Approach to Red Eye

Dr A.Najafi

Ophthalmologist, vitreoretinal fellowship

ARUMS

Learning Objectives

To obtain the expertise to:

1. **Recognize the common causes** of red eye conditions
2. **Adequately treat** the common causes of red eye conditions
3. **Recognize and refer** patients with red eye conditions that have higher-stakes diagnoses

RED EYE DISORDERS: AN ANATOMIC APPROACH

- Face
- Adnexa
  - Orbital area
  - Lids
  - Ocular movements
- Globe
  - Conjunctiva, sclera
  - Anterior chamber (using slit lamp if possible)
  - Intraocular pressure

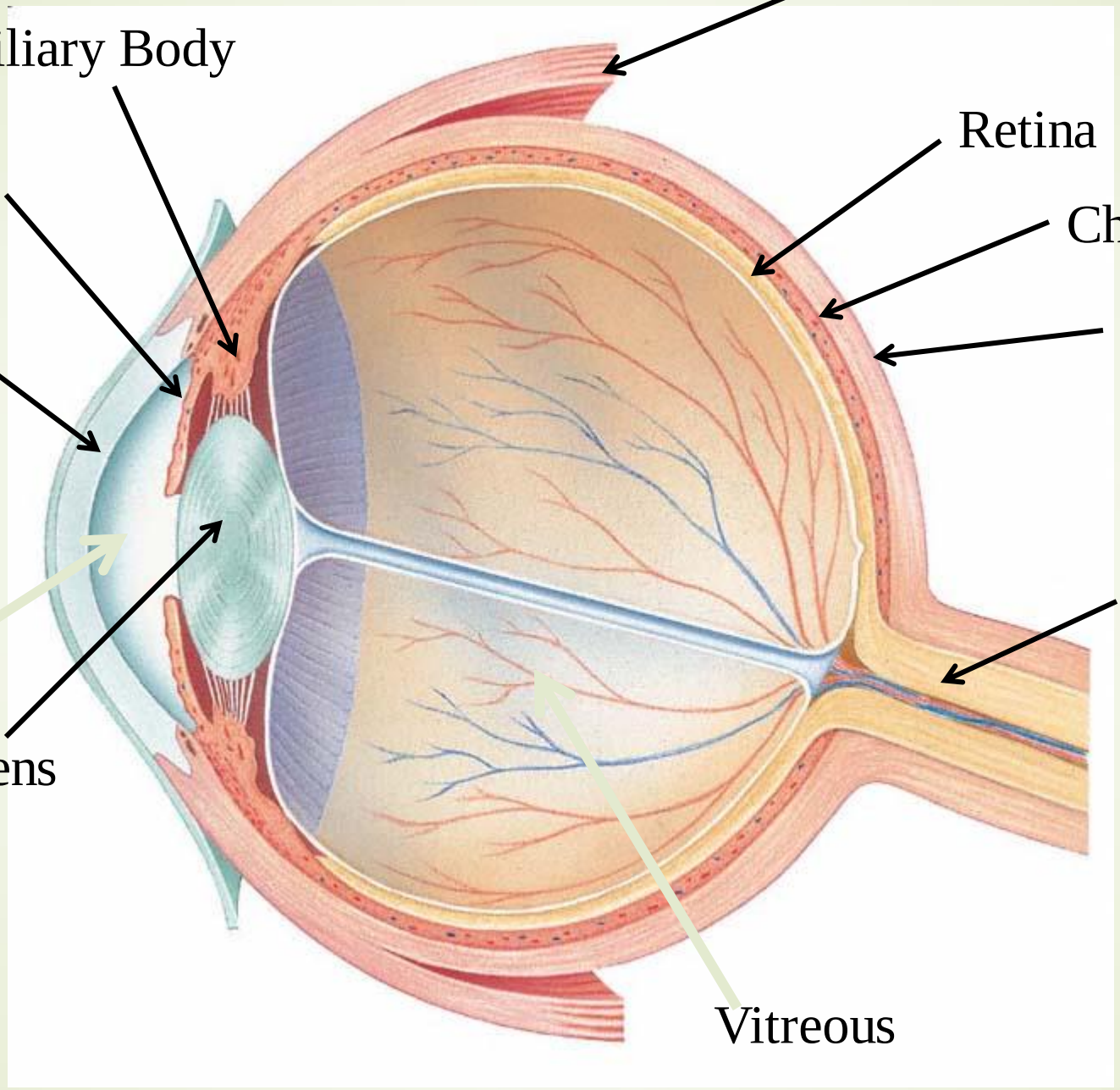
Rectus muscle
Ciliary Body
Retina
Iris
Choroid
Cornea
Sclera
Optic nerve
Aqueous
Lens
Vitreous

Ocular Adnexae

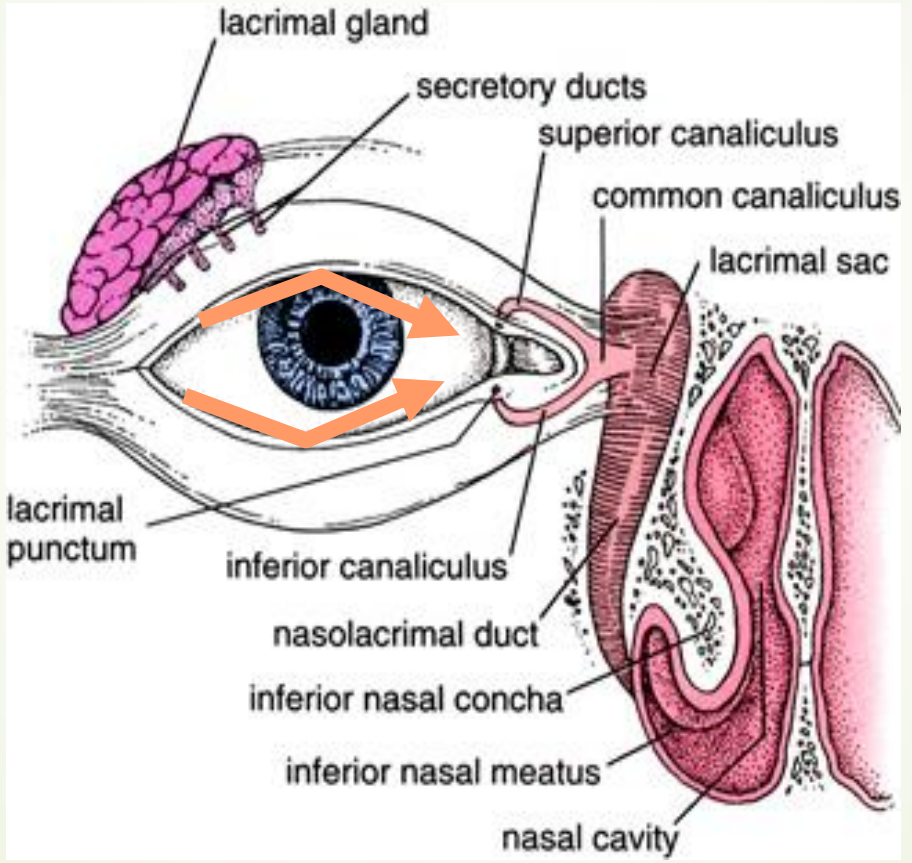

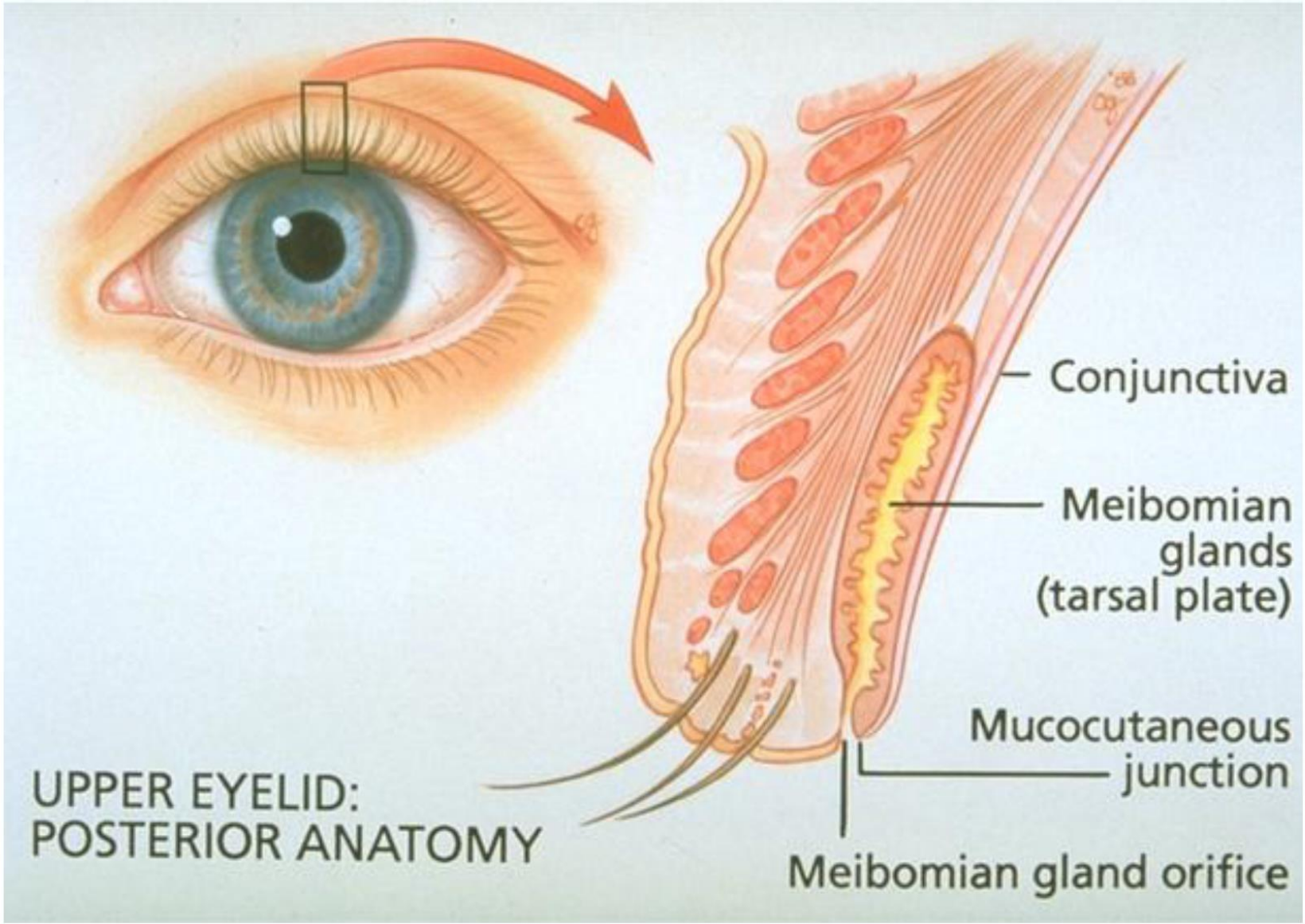
Conjunctiva
Meibomian glands (tarsal plate)
Mucocutaneous junction
Meibomian gland orifice
UPPER EYELID:
POSTERIOR ANATOMY

Ocular Adnexae

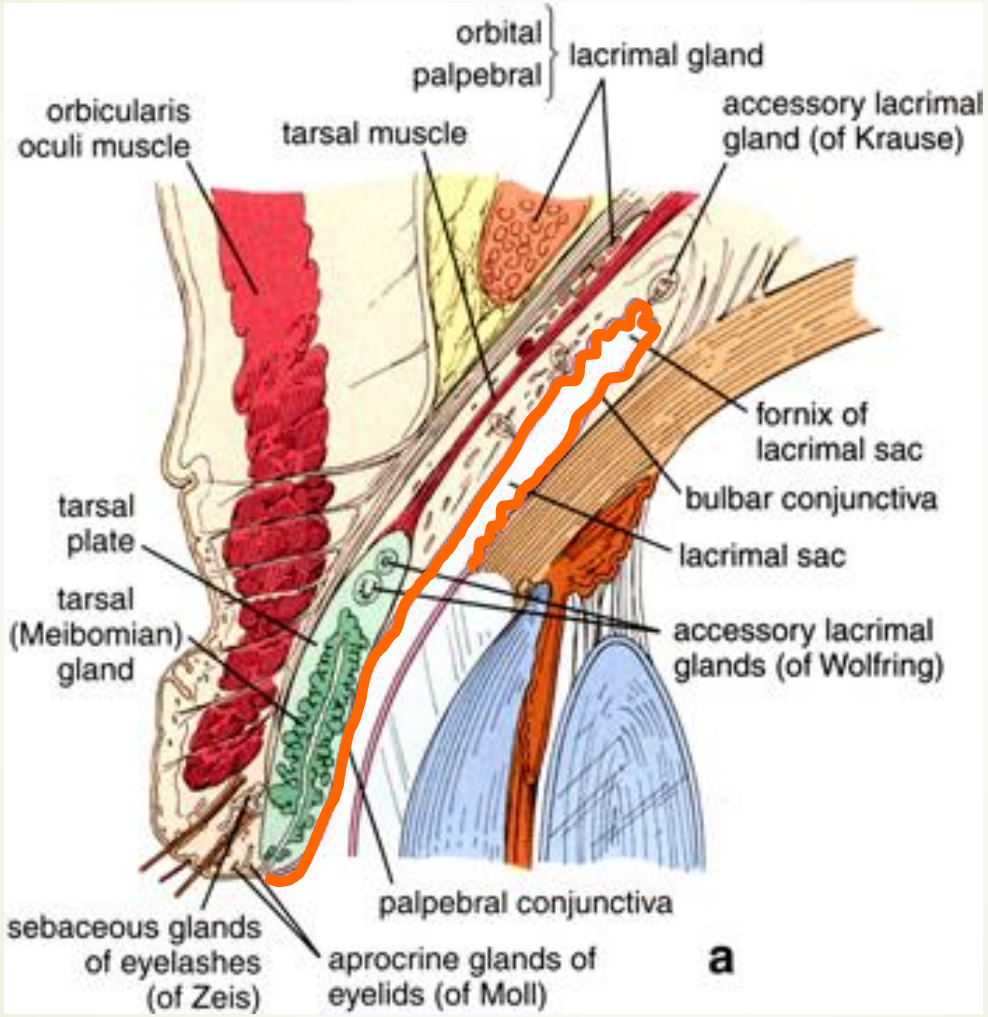

Conjunctiva Anatomy

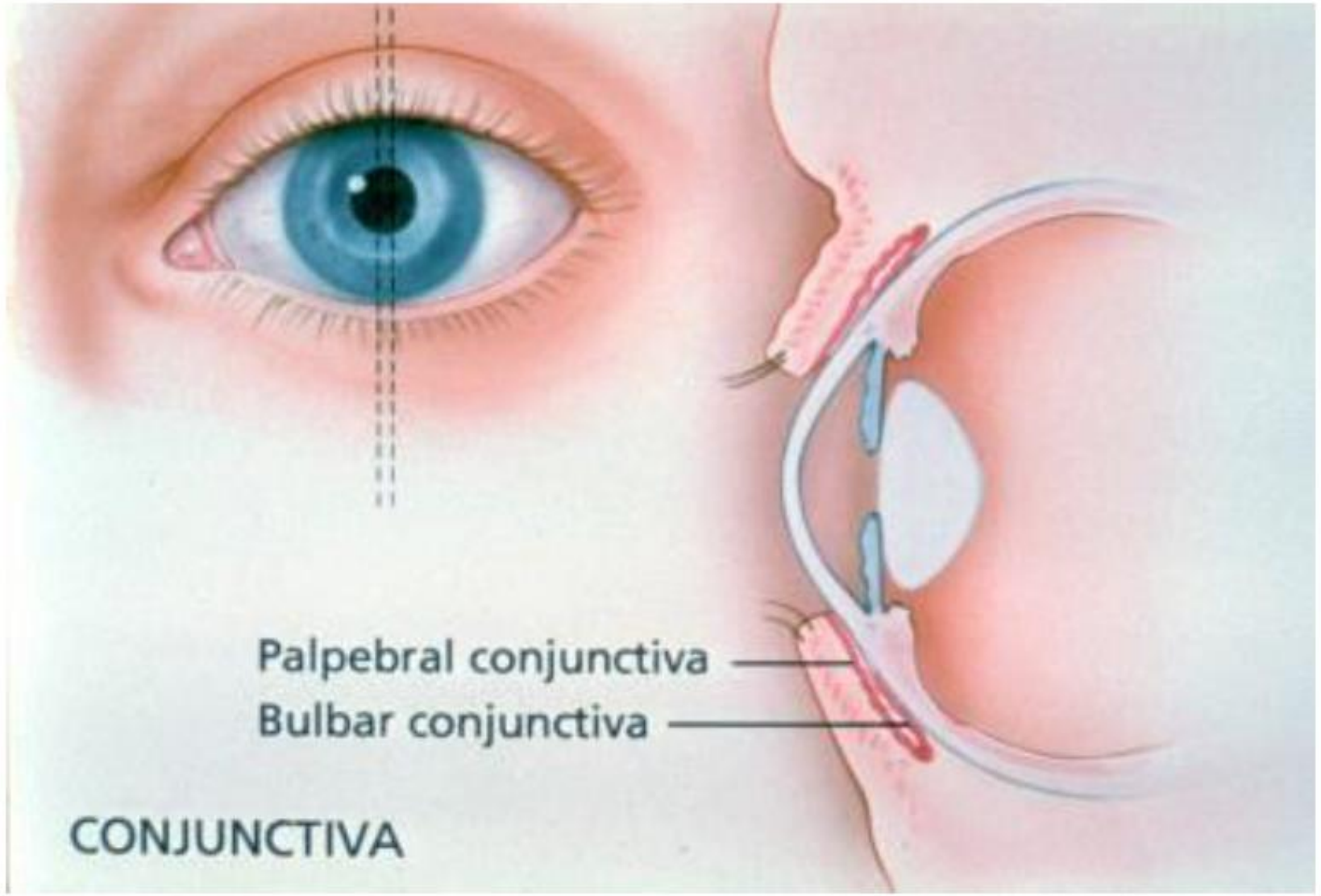

History

- Onset
- Location (unilateral /bilateral /sectoral)
- Pain/ discomfort (gritty, FB sensation, itch, deep ache)
- Photosensitivity
- Watering +/or discharge
- Change in vision (blurring, halos etc)
- Exposure to person with red eye
- Trauma
- Travel
- Contact lens wear
- Previous ocular history (eg hypermetropia)
- URTI
- PMHx eg autoimmune disease

HPI – Approach to the Patient with **Red** Eye

1. Unilateral or bilateral?
2. Intense eye **pain**?
3. **Foreign body** sensation?
4. **Contact lens** wear?
5. **Discharge**? Type?
6. **Itch**?
7. Eyelid **edema**?
8. Do the eyelids have **lumps**?
9. Do the eyes **burn**?
10. **Photophobia**?
11. Loss of **vision**?
12. Using ocular **medications**?
    - Topical or oral

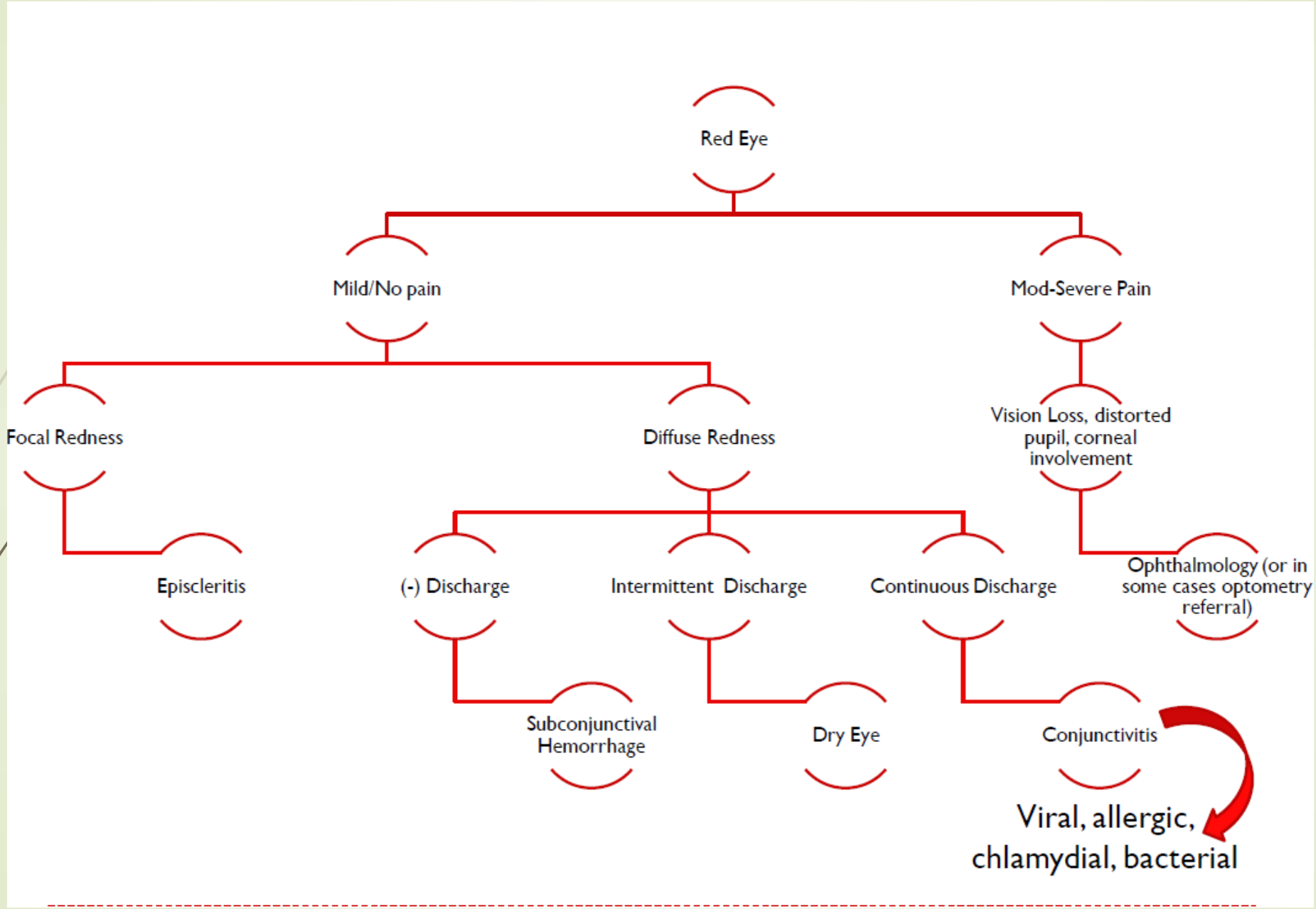
Red Eye
Mild/No pain
Mod-Severe Pain
Focal Redness
Diffuse Redness
Vision Loss, distorted pupil, corneal involvement
Episcleritis
(-) Discharge
Intermittent Discharge
Continuous Discharge
Ophthalmology (or in some cases optometry referral)
Subconjunctival Hemorrhage
Dry Eye
Conjunctivitis
Viral, allergic, chlamydial, bacterial

Examination

- Inspect whole patient
- Visual acuity- each eye + PH
- Pupil reactions
- Lymphadenopathy- preauricular nodes
- Eyelids
- Conjunctiva (bulbar and palpebral)
- Cornea (clarity, staining with fluorescein, sensation)
- Anterior chamber (depth)
- Pupils shape/ reaction to light / accomodation
- Fundoscopy
- Eye movements

Equipment needed to evaluate red eye

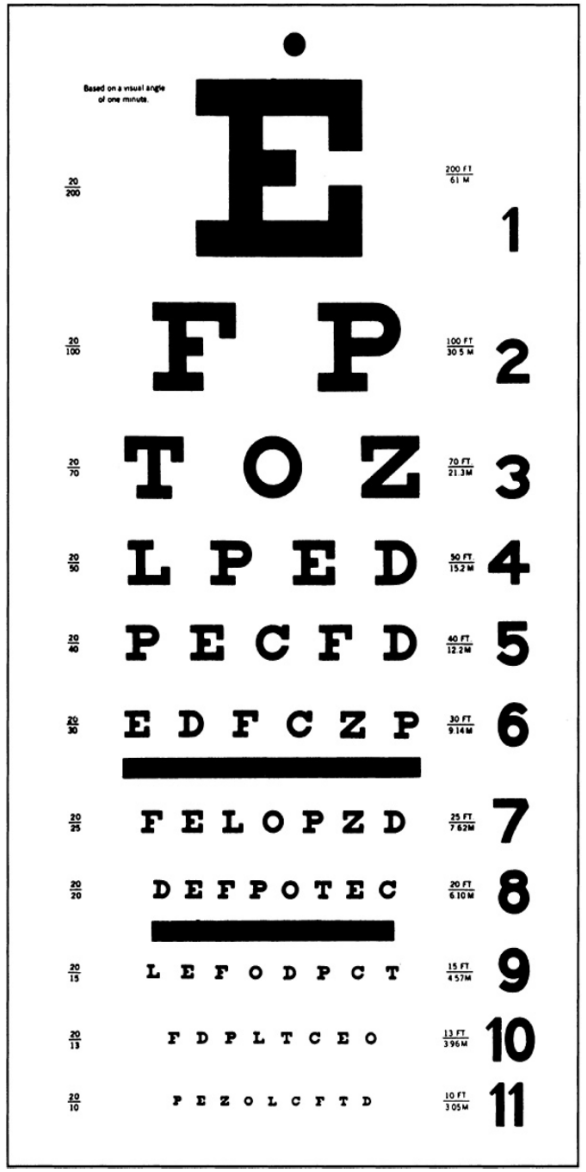

Refer red eye with vision loss to

ophthalmologist for evaluation

DIFFERENTIATE RED EYE DISORDERS

- Needs immediate treatment
- Needs treatment within a few days
- Does not require treatment

SUBJECTIVE EYE COMPLAINTS

- Decreased vision
- Pain
- Redness

Characterize the complaint through history and exam.

TYPES OF RED EYE DISORDERS

- Mechanical trauma
- Chemical trauma
- Inflammation/infection

Causes

- Lids

1. Blepharitis
2. Marginal keratitis
3. Trichiasis
4. Chalazion/ Stye
5. Sub-tarsal foreign body
6. Canaliculitis
7. Dacrocystitis

- Conjunctiva

1. Bacterial conjunctivitis
2. Gonococcal conjunctivitis
3. Chlamydial conjunctivitis
4. Viral conjunctivitis
5. Allergic conjunctivitis
6. Subconjunctival haemorrhage
7. Episcleritis vs Scleritis
8. Pingueculum
9. Pterygium

- Cornea

1. Bacterial keratitis
2. Herpetic keratitis
3. Foreign body

- Anterior chamber

1. Anterior uveitis/ iritis vs vitritis

- Acute angle closure
- Herpes Zoster ophthalmicus
- Trauma
- Orbital cellulitis vs pre-septal cellulitis

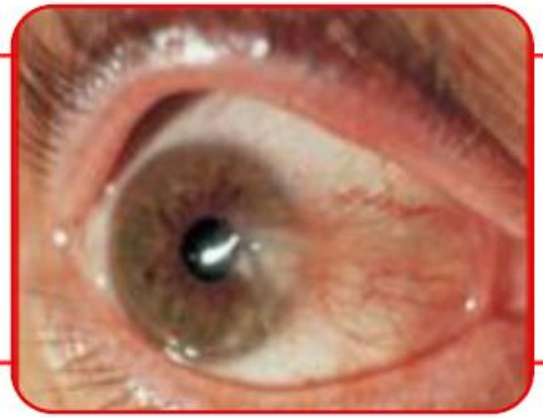

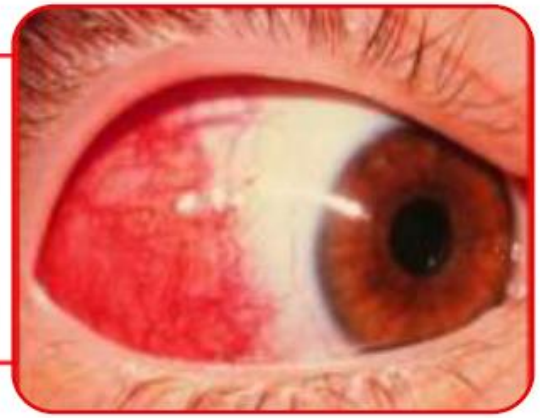

Common	Less Common/Less Serious	Less Common/More Serious
Conjunctivitis: (bacterial, viral, allergic)	Episcleritis	Viral Keratitis
Subconjunctival hemorrhage	Pingueculum	Uveitis
Corneal abrasion	Pterygium	Scleritis
Blepharitis		Angle Closure Glaucoma
Hordeolum (stye)		Chemical Burn

ETIOLOGIES OF RED EYE

1. Chemical injury
2. Angle-closure glaucoma
3. Ocular foreign body
4. Corneal abrasion
5. Uveitis
6. Conjunctivitis
7. Ocular surface disease
8. Subconjunctival hemorrhage

RED EYE: POSSIBLE CAUSES

- Trauma
- Chemicals
- Infection
- Allergy
- Systemic conditions

RED EYE: CAUSE AND EFFECT

Symptom	Cause
Itching	Allergy
Burning	Lid disorders, dry eye
Foreign body sensation	Foreign body, corneal abrasion
Localized lid tenderness	Hordeolum, chalazion

RED EYE: CAUSE AND EFFECT (Continued)

Symptom	Cause
Deep, intense pain	Corneal abrasions, scleritis, iritis, acute glaucoma, sinusitis, etc.
Photophobia	Corneal abrasions, iritis, acute glaucoma
Halo vision	Corneal edema (acute glaucoma, uveitis)

COMMON RED EYE DISORDERS: TREATMENT INDICATED

- Hordeolum
- Chalazion
- Blepharitis
- Conjunctivitis
- Subconjunctival hemorrhage
- Dry eyes
- Corneal abrasions (most)

VISION-THREATENING RED EYE SIGNS & SYMPTOMS: REFERRAL INDICATED

- Decreased vision
- Ocular pain
- Photophobia
- Circumlimbal redness
- Corneal edema
- Corneal ulcers/ dendrites
- Abnormal pupil
- Elevated IOP

VISION-THREATENING RED EYE DISORDERS: URGENT REFERRAL

- Orbital cellulitis
- Scleritis
- Chemical injury
- Corneal infection
- Hyphema
- Iritis
- Acute glaucoma

Infectious causes of Red eye

Dr A.Najafi

Ophthalmologist, Vitreoretinal fellowship

ARUMS

BLEPHARITIS

- Inflammation of lid margin
- Associated with dry eyes
- Seborrhea causes dried skin and wax on base of lashes
- May have Staphylococcal infection
- Symptoms: lid burning, lash mattering

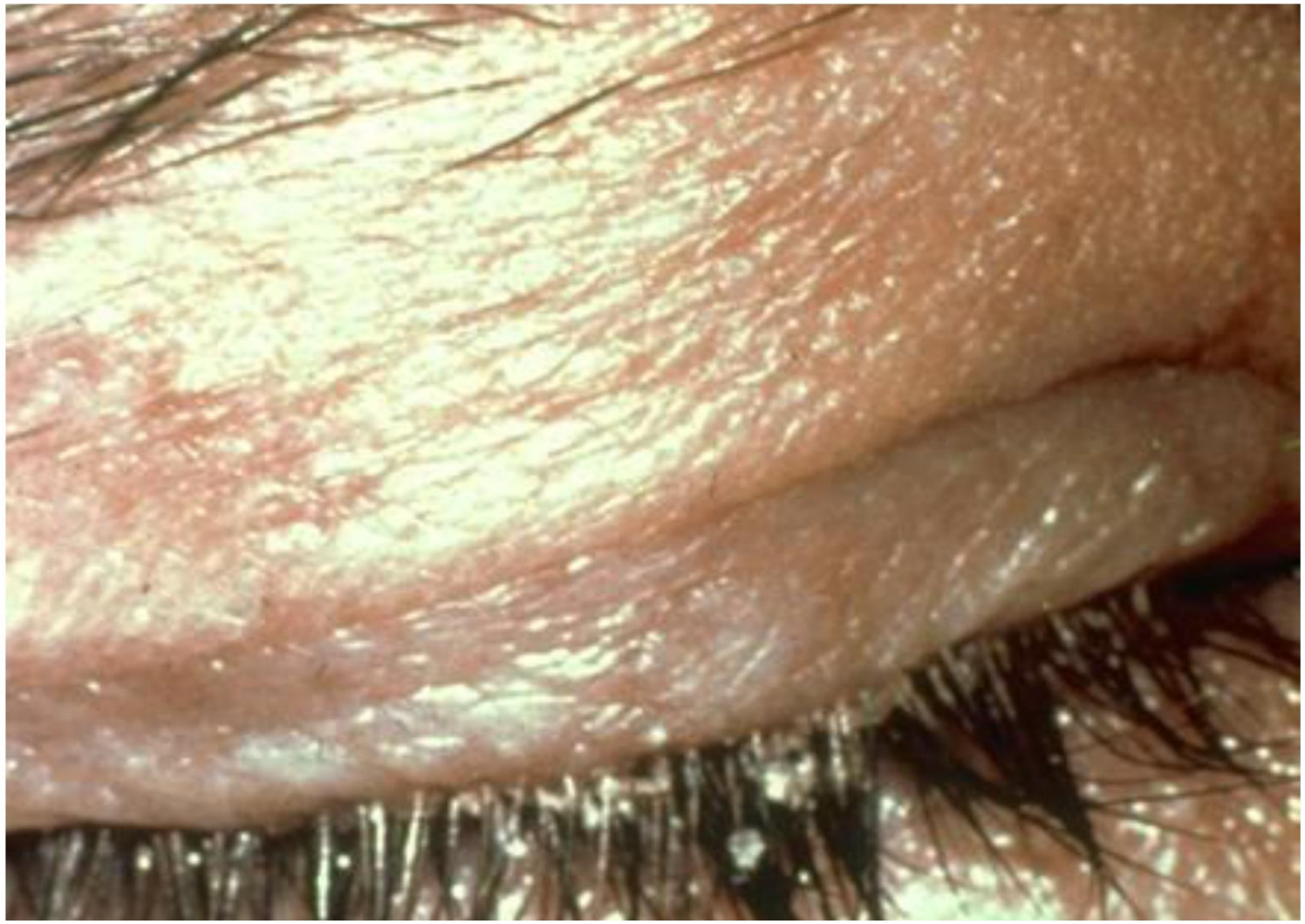

Collarettes on eyelashes of patient with blepharitis

BLEPHARITIS: TREATMENT

- Lid and face hygiene
  - Warm compresses to loosen deposits on lid margin
  - Gentle scrubbing with nonirritating shampoo or scrub pads
- Artificial tears to alleviate dry eye
- Antibiotic or antibiotic-corticosteroid ointment
- Oral doxycycline 100 mg daily for refractory cases

Preseptal cellulitis

Orbital cellulitis

ORBITAL CELLULITIS: SIGNS AND SYMPTOMS

- External signs: redness, swelling
- Motility impaired, painful
- ± Proptosis
- Often fever and leukocytosis
- ± Optic nerve: decreased vision, afferent pupillary defect, disc edema

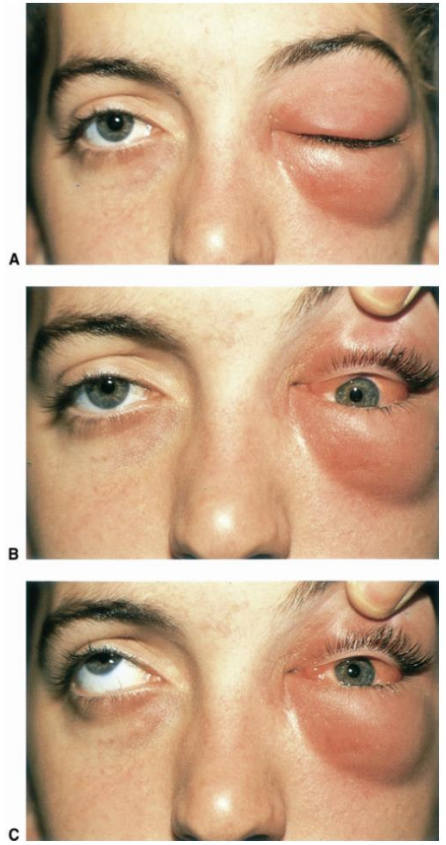

ORBITAL CELLULITIS: MANAGEMENT

- Hospitalization
- Ophthalmology consult
- Eye consult
- Blood culture
- Orbital CT scan
- ENT consult if pre-existing sinus disease

ORBITAL CELLULITIS: TREATMENT

- IV antibiotics stat: Staphylococcus, Streptococcus, H. influenzae
- Surgical debridement if fungus, no improvement, or subperiosteal abscess
- Complications: cavernous sinus thrombosis, meningitis

lacrimal apparatus.

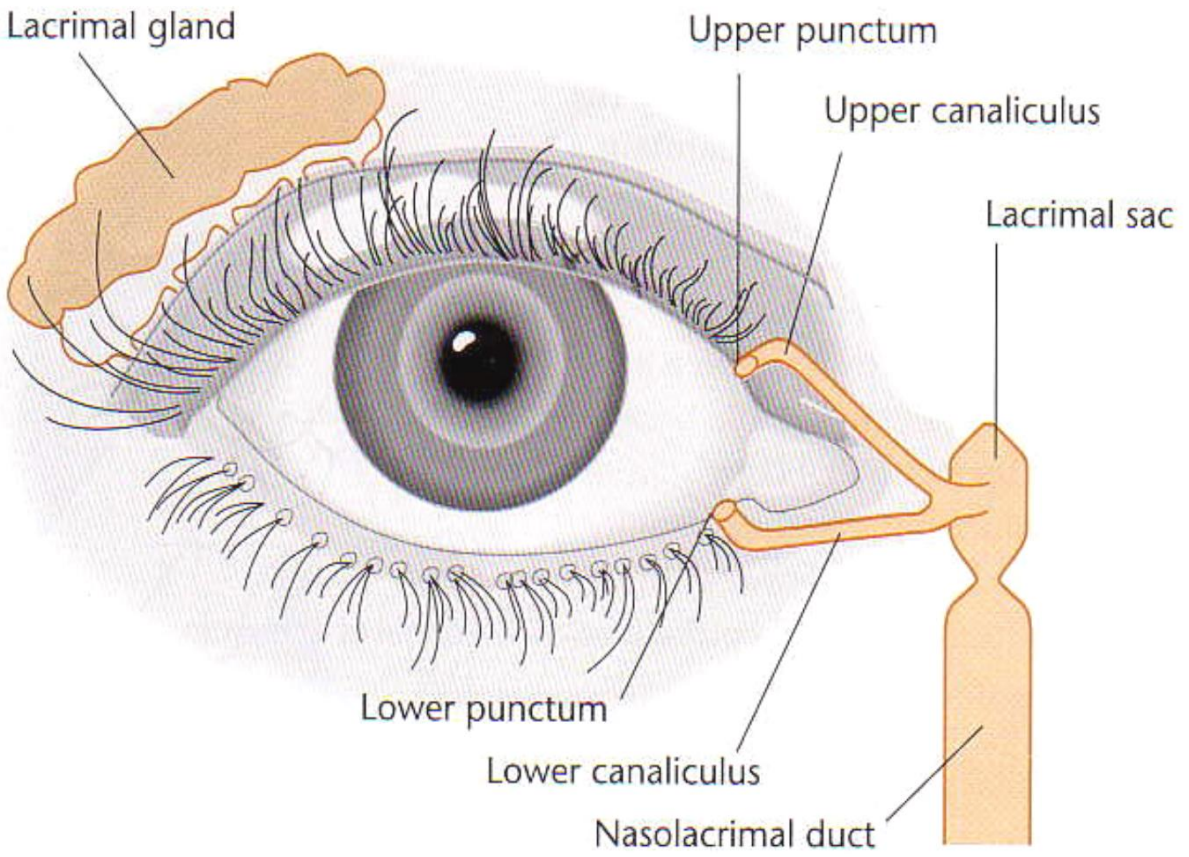

Lacrimal system

Dacryocystitis

NASOLACRIMAL DUCT OBSTRUCTION: CONGENITAL

- Massage tear sac daily
- Probing, irrigation, if chronic
- Systemic antibiotics if infected

NASOLACRIMAL DUCT OBSTRUCTION: ACQUIRED

- Trauma a common cause
- Systemic antibiotics if infected
- Surgical procedure after one episode of dacryocystitis (dacryocystorhinostomy) prn

Dilated conjunctival blood vessels

ADULT CONJUNCTIVITIS: MAJOR CAUSES

- Bacterial
- Viral
- Allergic

CONJUNCTIVITIS: DISCHARGE

Discharge	Cause
Purulent	Bacterial
Clear	Viral*
Watery, with stringy; white mucus	Allergic**

* Preauricular lymphadenopathy signals viral infection
** Itching often accompanies

Bacterial Conjunctivitis

- Often unilateral
- Usually purulent discharge

BACTERIAL CONJUNCTIVITIS: COMMON CAUSES

- *Staphylococcus* (skin)
- *Streptococcus* (respiratory)
- *Haemophilus* (respiratory)

BACTERIAL CONJUNCTIVITIS TREATMENT

- Topical antibiotic: qid x 7 days (aminoglycoside, erythromycin, fluoroquinolone, sulfacetamide, or trimethoprim-polymyxin)
- Warm compresses
- Refer if not markedly improved in 3 days

Copious purulent discharge: Suspect Neisseria gonorrhoeae.

VIRAL CONJUNCTIVITIS

- Watery discharge
- Highly contagious
- Palpable preauricular lymph node
- History of URI, sore throat, fever common

If pain, photophobia, or decreased vision, refer.

Viral Conjunctivitis

Viral Conjunctivitis

- Usually starts in one eye and frequently spreads to other eye
- Profuse watery discharge
- Diffuse conjunctival injection
- Often seen in epidemics

- Behavioral Treatment – may not affect duration of symptoms
  - Cold compress
  - Scrupulous hygiene
  - Avoidance of direct contact with others

NEONATAL CONJUNCTIVITIS: CAUSES

- Bacteria (N. gonorrhoeae, 2–4 days)
- Bacteria (Staphylococcus, Streptococcus, 3–5 days)
- Chlamydia (5–12 days)
- Viruses (eg, herpes, from mother)

Neonatal gonococcal conjunctivitis

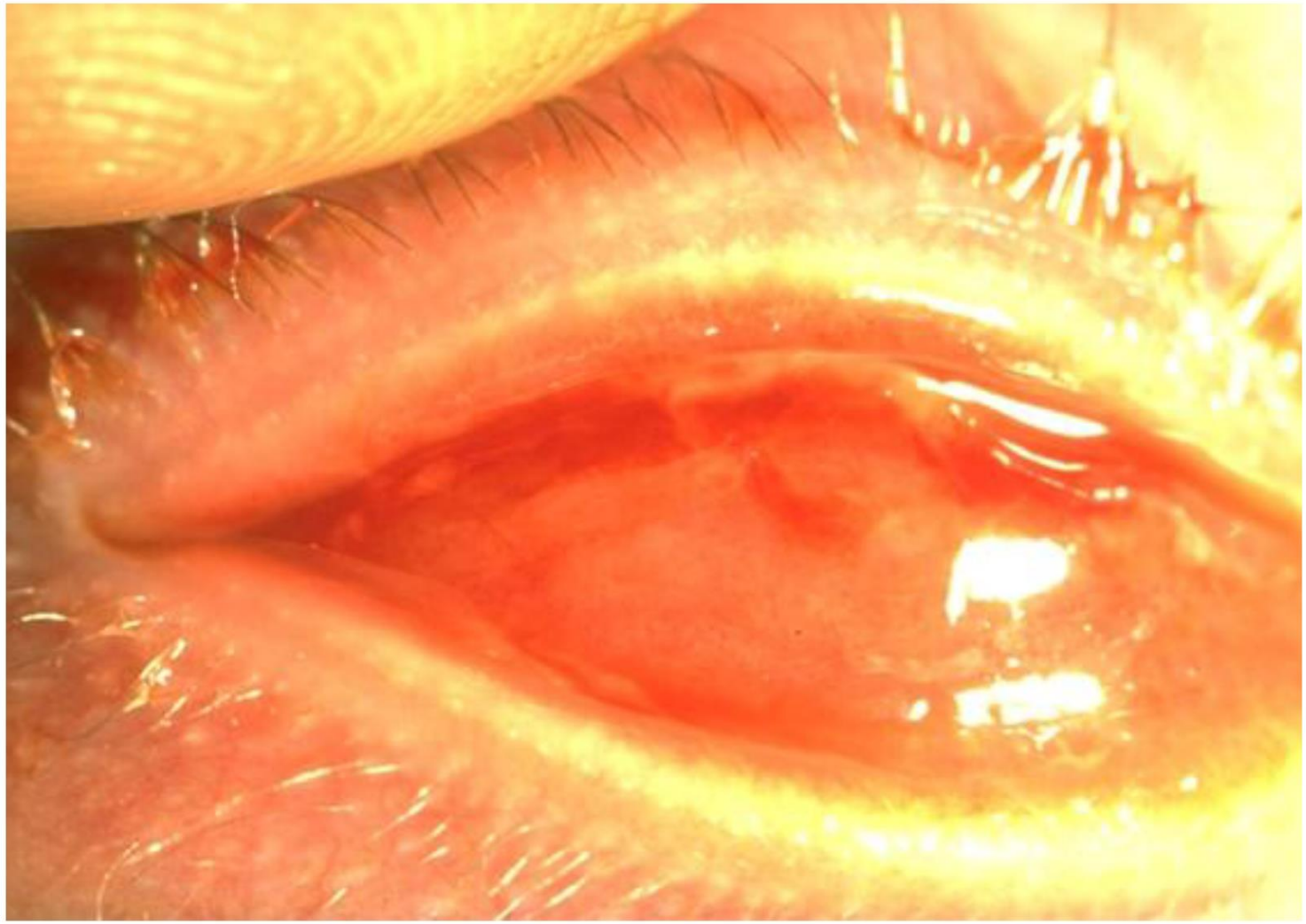

Neonatal chlamydial conjunctivitis

Chlamydial & Gonococcal Conjunctivitis

- *Copious/severe* purulent discharge***

- Chlamydial Conjunctivitis Treatment
  - **Azithromycin 1 g p.o. single dose**
  - Alt: Doxycycline (Vibramycin) 100 mg p.o. BID X 7-10 days
  - Add-on: Erythromycin (Ery-Tab) ung BID-TID to help suppress ocular manifestations
    - Not FDA approved for this indication
  - Treat partners

- Gonococcal Conjunctivitis Treatment
  - **Ceftriaxone 1 gram IM in single dose followed by 2-3 weeks of oral Ab therapy**
    - Fluoroquinolones q1-2h
  - **Topical Antibiotic Therapy:**
    - gentamicin, erythromycin or bacitracin every 2 hours x 2days, then 5x daily until resolved
  - **Ideally daily follow-up for ocular symptoms*****

INFECTIOUS KERATITIS

- Frequently result from mechanical trauma
- Can cause permanent scarring and decreased vision
- Early detection, aggressive therapy are vital

Bacterial infection of the cornea

Primary herpes simplex infection

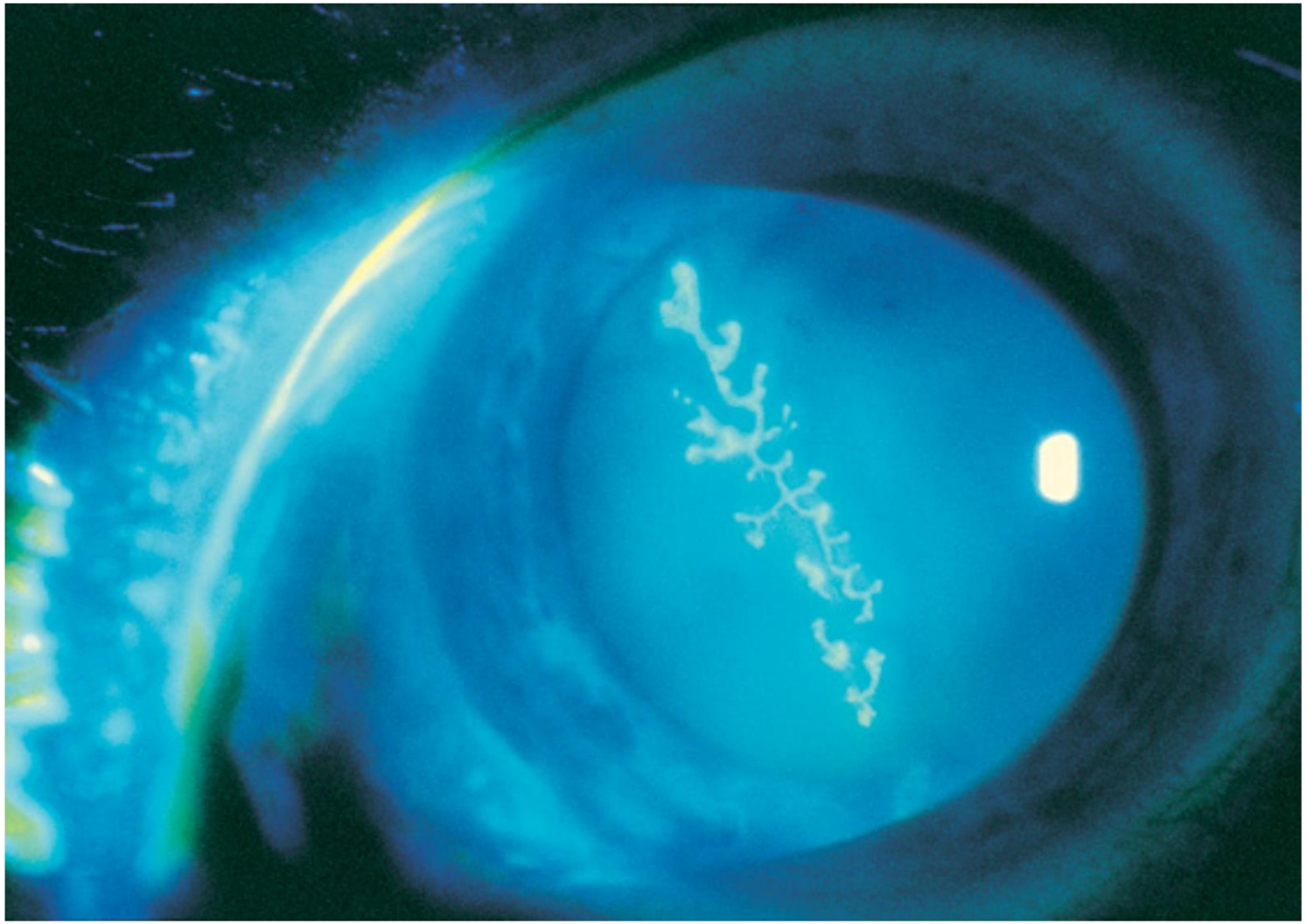

Corneal herpes simplex dendrites, stained with fluorescein

Acute endophthalmithis

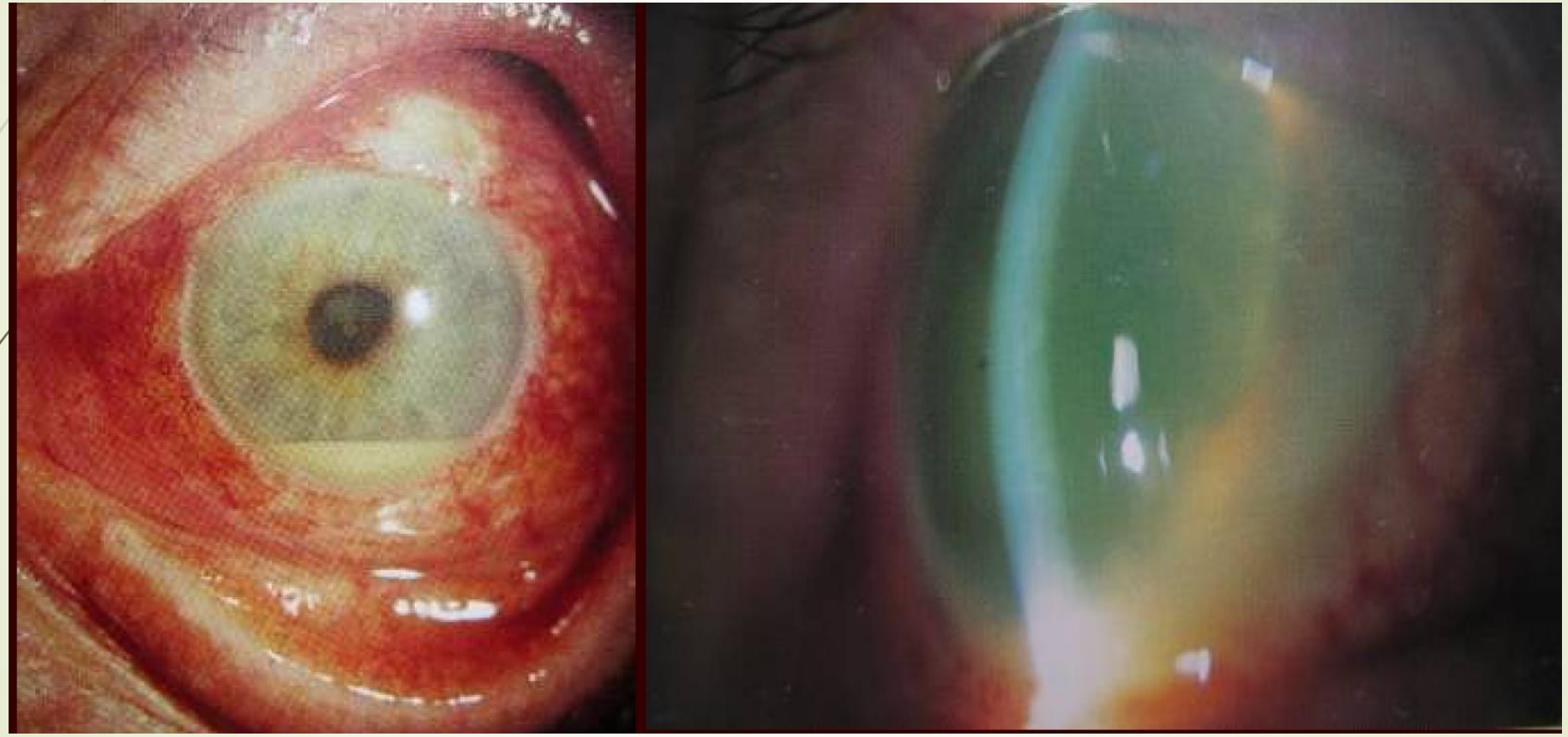

- Endophthalmitis is an inflammatory condition of the intraocular cavities (ie, the aqueous and/or vitreous humor), usually caused by infection.
- Noninfectious (sterile) endophthalmitis may result from various causes such as retained native lens material after an operation or from toxic agents.
- Panophthalmitis is inflammation of all coats of the eye, including intraocular structures.

- **A. Exogenous**
- 1. Postsurgical
    - a. Acute onset
    - b. Delayed onset
    - c. Bleb associated
- 2. Nonsurgical
    - a. Post-traumatic
- **B. Endogenous**

Symptoms

- Blurred vision (94%)
- Red eye (82%)
- Pain (74%)
- Swollen lid (34%)
- Photophobia
- Purulent discharge

Emergency Department Care

- Once the diagnosis has been made, or strongly considered, prompt consultation to an ophthalmologist is needed.
- Treatment depends on the underlying cause of endophthalmitis.
- Final visual outcome is heavily dependent on timely recognition and treatment.
- Although multiple different approaches to and advances in treatment have been made, according to recent data, the rate of preservation of visual acuity has not changed significantly since 1995

Treatment of postoperative endophthalmitis

- Pars plana vitrectomy or vitreous aspiration may be performed by an ophthalmologist with administration of intravitreal antibiotics (ie, vancomycin, amikacin, ceftazidime).
- Consider systemic antibiotic administration as well as intravitreal steroids.

Non Infectious Causes of Red Eye

Dr A.Najafi

Ophthalmologis,vitreoretinal fellowship

ARUMS

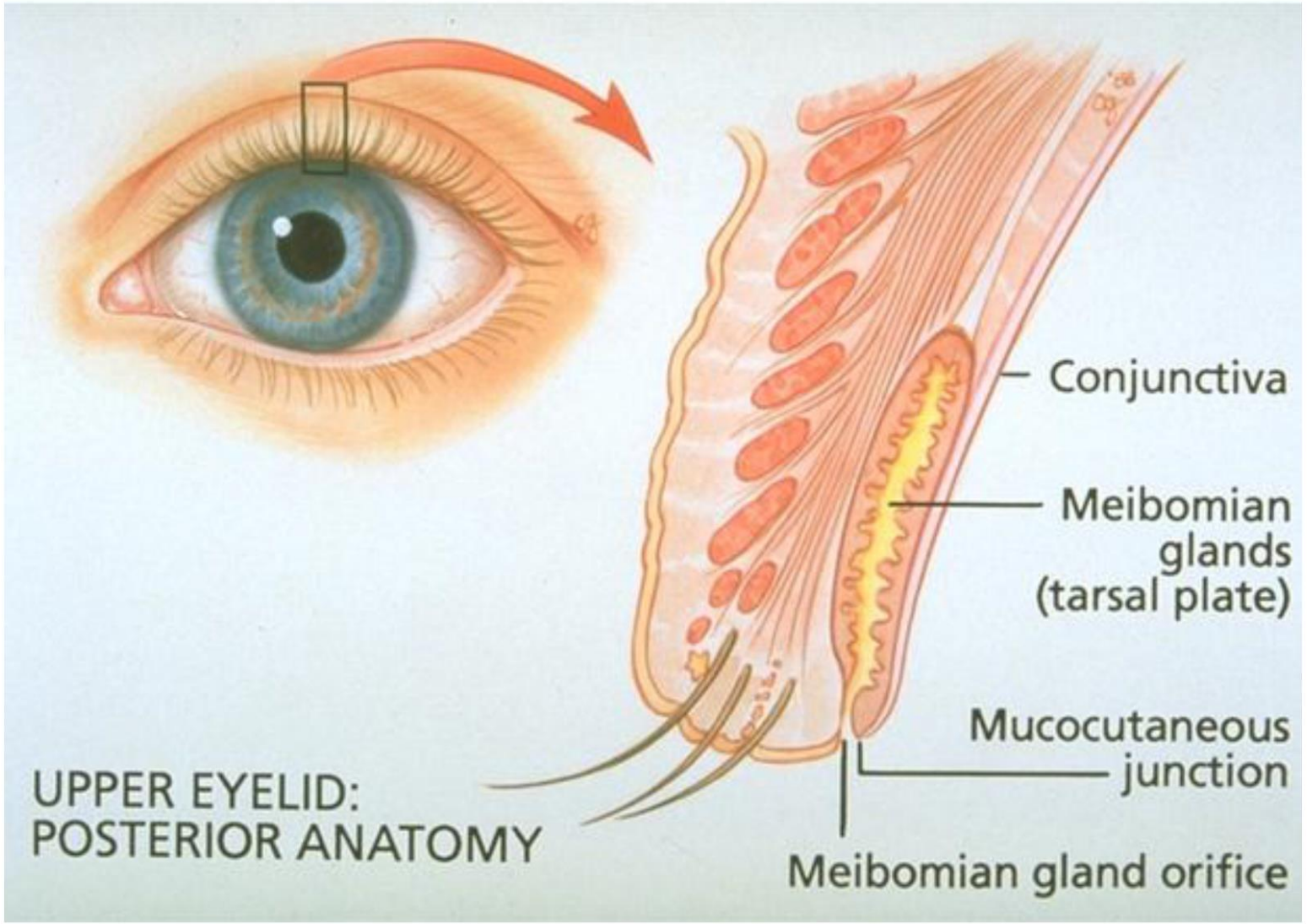
Conjunctiva
Meibomian glands (tarsal plate)
Mucocutaneous junction
Meibomian gland orifice
UPPER EYELID:
POSTERIOR ANATOMY

Chalazion

HORDEOLUM/CHALAZION: TREATMENT

- **Goal**
  - To promote drainage
- **Treatment**
  - Acute/subacute: Warm-hot compresses, tid
  - Chronic: Refer to ophthalmologist

ADULT CONJUNCTIVITIS: MAJOR CAUSES

- Bacterial
- Viral
- Allergic

CONJUNCTIVITIS: DISCHARGE

Discharge	Cause
Purulent	Bacterial
Clear	Viral*
Watery, with stringy; white mucus	Allergic**

* Preauricular lymphadenopathy signals viral infection
** Itching often accompanies

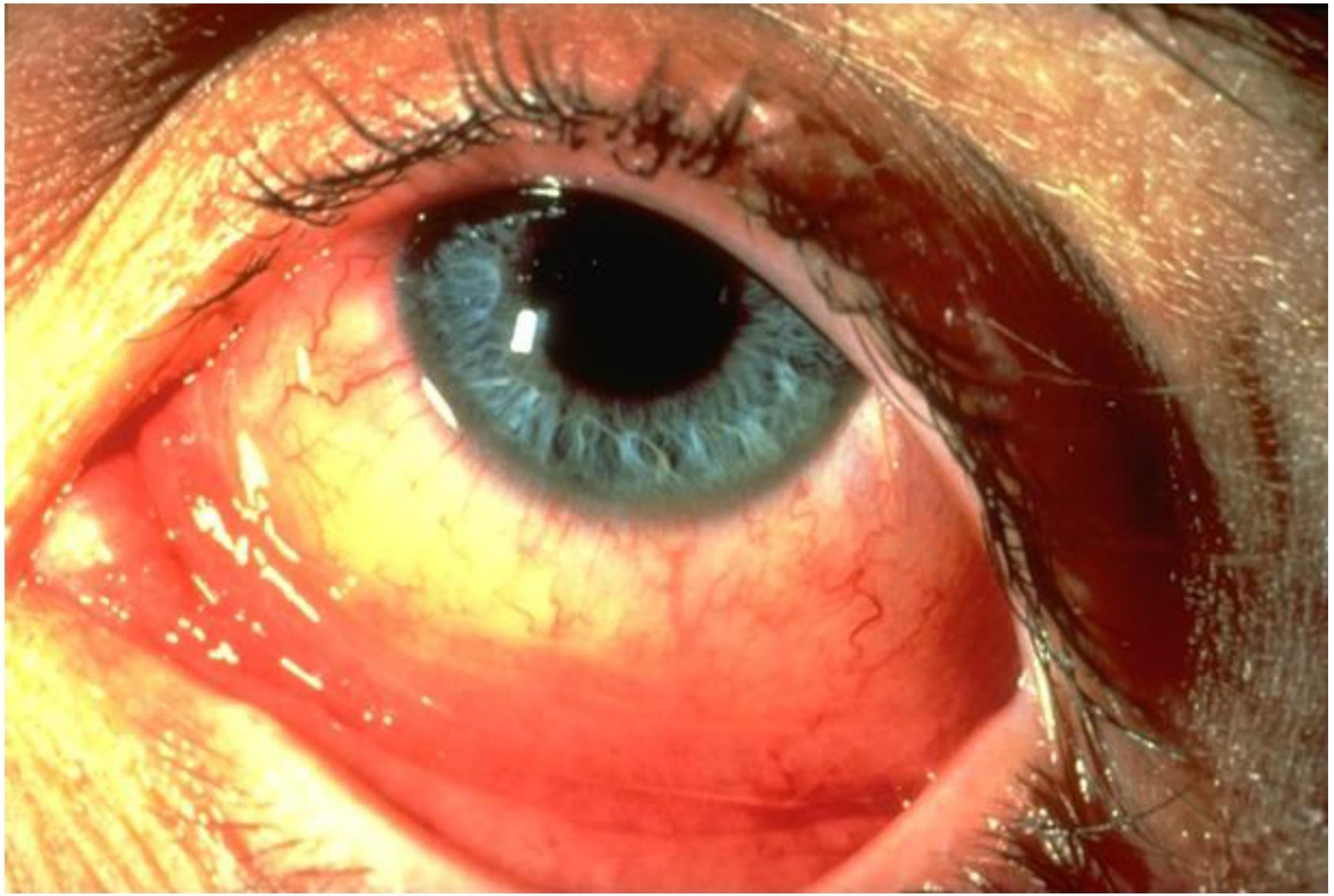

Allergic conjunctivitis

ALLERGIC CONJUNCTIVITIS

- Associated conditions: hay fever, asthma, eczema
- Contact allergy: chemicals, cosmetics, pollen
- Treatment: topical antihistamine/ decongestant drops
- Systemic antihistamines if necessary for systemic disease

Refer refractory cases.

Allergic Conjunctivitis

- Usually in both eyes
- Often accompanies allergic rhinitis
- Itchy eyes
- Mucoid discharge
- Cobble-stoning

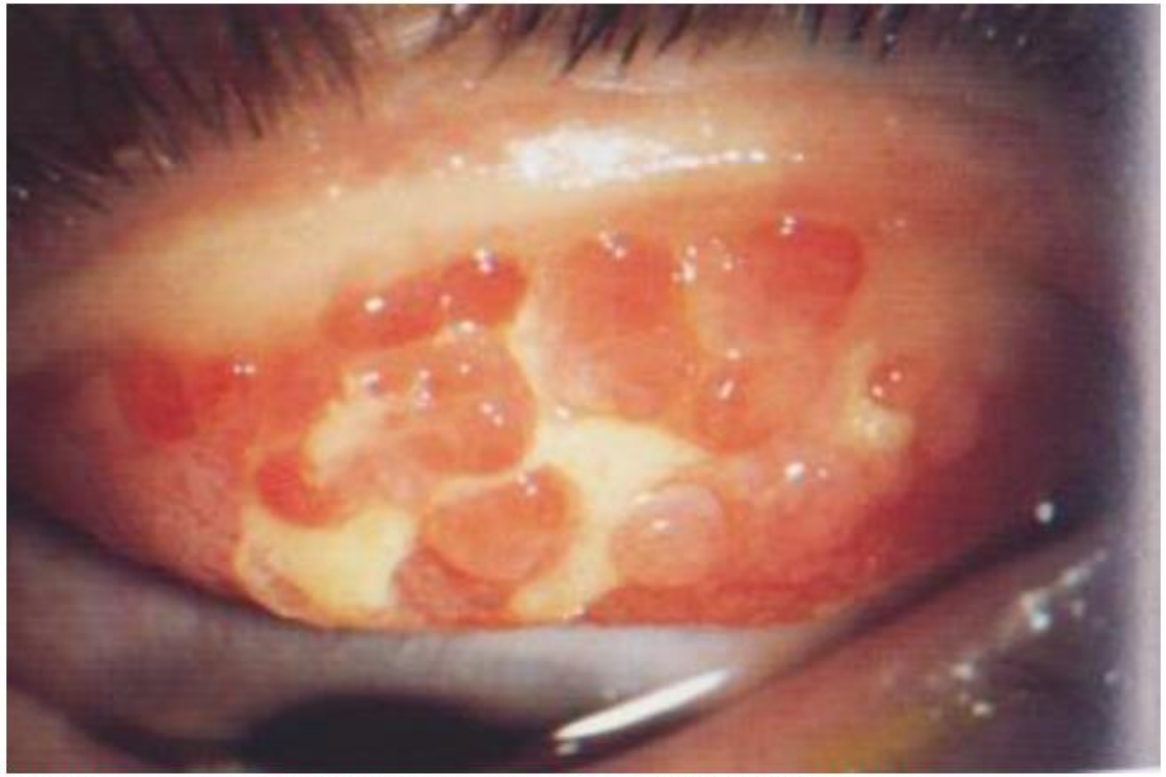

http://www.physicianbyte.com/CommonEyeDiseasesInChildHood.aspx

Allergic Conjunctivitis Treatment

H1 Antagonists

- Emedastine (Emadine)
- Naphazoline/pheriramine (Naphcon-A, Opcon-A, Visine-A)
- **Ketotifen (Alaway, Zaditor)**

Mast Cell Stabilizers (chronic allergies)

- Cromolyn (Crolom)
- Lodoxamide (Alomide)
- Olopatadine 0.1% (Pataday)

Combination

- Azelastine (Optivar)
- Epinastine (Elestat)
  - H1 & H2 antagonist
- Nedrocomil (Alocril)
- Olopatadine 0.1% (Patanol)

NSAID's / Steroids

- Ketorolac (Aclar) - NSAID
- Diclofenac (Voltaren) - NSAID
- Loteprednol (Alrex, Lotemax) - Steroid

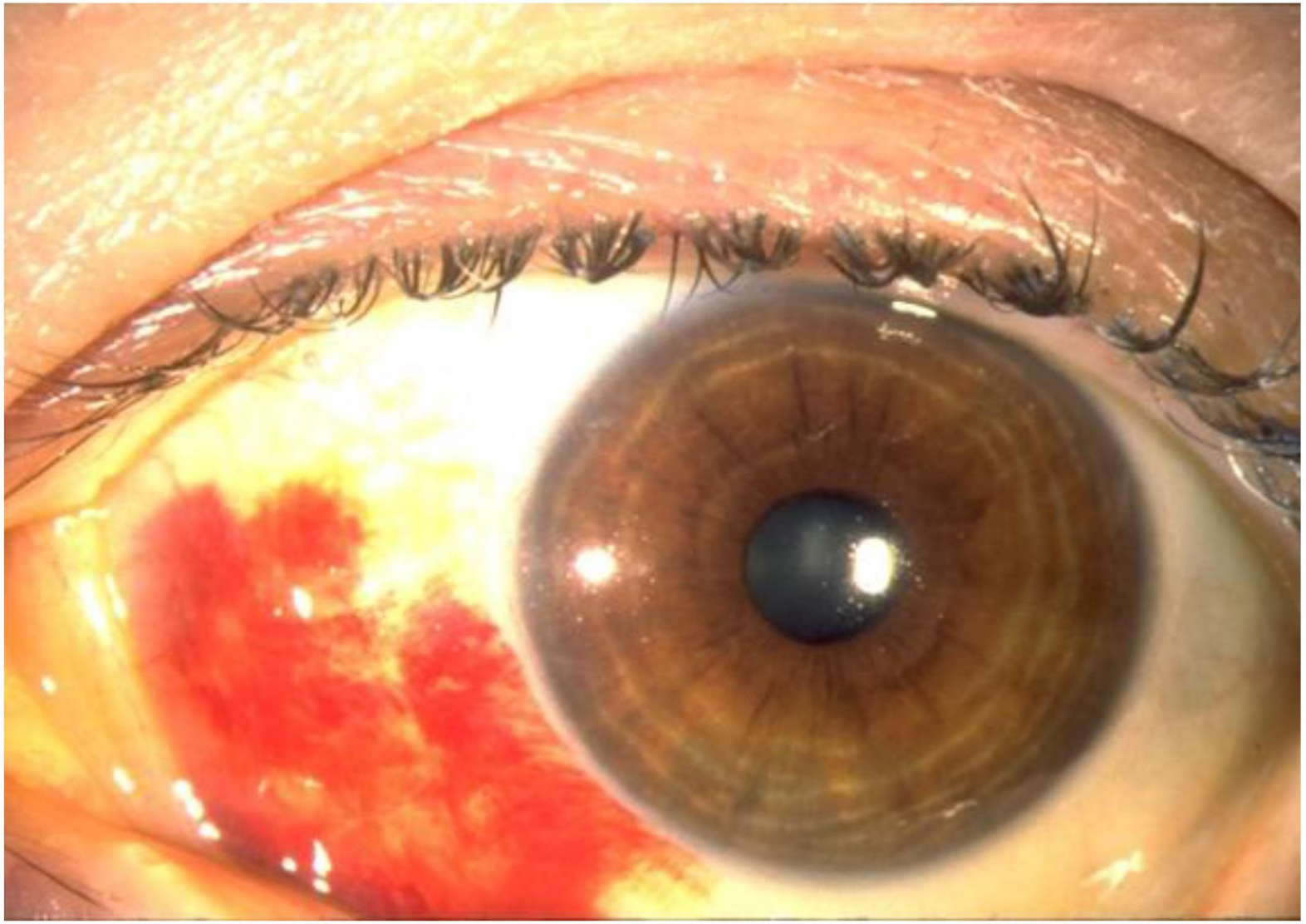

Subconjunctival hemorrhage

Subconjunctival Hemorrhage

- No pain or visual changes
  - If pain or visual acuity decrease are present - refer
- Should resolve in 2 – 3 weeks
- Potential Causes:
  - Spontaneous
  - Trauma
  - Hypertension
  - Bleeding disorders
  - Increased intrathoracic pressure (Valsalva)
    - Straining
    - Coughing
    - Retching

TEARS AND DRY EYES

- Tear functions:
  - Lubrication
  - Bacteriostatic and immunologic functions
- Dry eye (keratoconjunctivitis sicca) is a tear deficiency state

TEAR DEFICIENCY STATES: SYMPTOMS

- Burning
- Foreign-body sensation
- Paradoxical reflex tearing
- Symptoms can be made worse by reading, computer use, television, driving, lengthy air travel

TEAR DEFICIENCY STATES: ASSOCIATED CONDITIONS

- Aging
- Rheumatoid arthritis
- Stevens-Johnson syndrome
- Chemical injuries
- Ocular pemphigoid
- Systemic medications

DRY EYES: TREATMENT

- Artificial tears, cyclosporine drops
- Nonpreserved artificial tears
- Lubricating ointment at bedtime
- Punctal occlusion
- Counseling about activities that make dry eyes worse

EXPOSURE KERATITIS: CAUSES AND MANAGEMENT

- Due to incomplete lid closure
- Manage with lubricating solutions/ ointments
- Tape lids shut at night
- Do not patch
- Refer severe cases

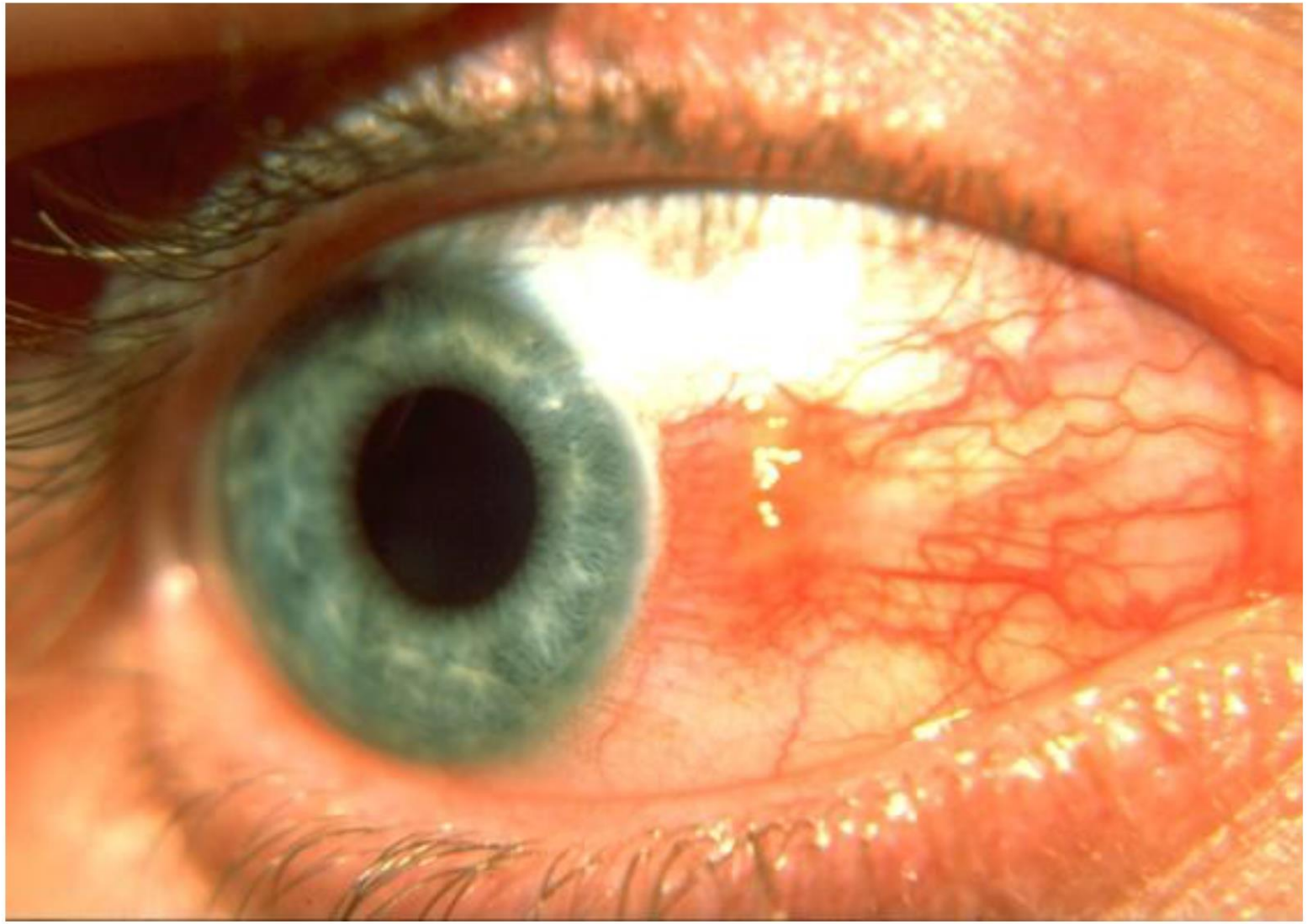

Pinguecula

Pingueculum

- Characteristics
  - Yellowish patch/bump on the bulbar conjunctiva
  - Deposit of fat/protein
  - Non-cancerous
  - Redness with irritation or inflammation
  - May cause a foreign body sensation
  - Does not grow onto cornea or effect vision
  - Can become acutely inflammed

Pterygium

Pterygium

- Characteristics
  - Associated with chronic sun exposure (Surfer's Eye)
  - Fibrovascular conjunctival tissue
  - Triangular (Insect wing shape)
  - Non-cancerous
  - Starts peripherally and moved centrally onto cornea
  - Effect on vision only if approaches the visual axis
    - Can be referred for surgical removal

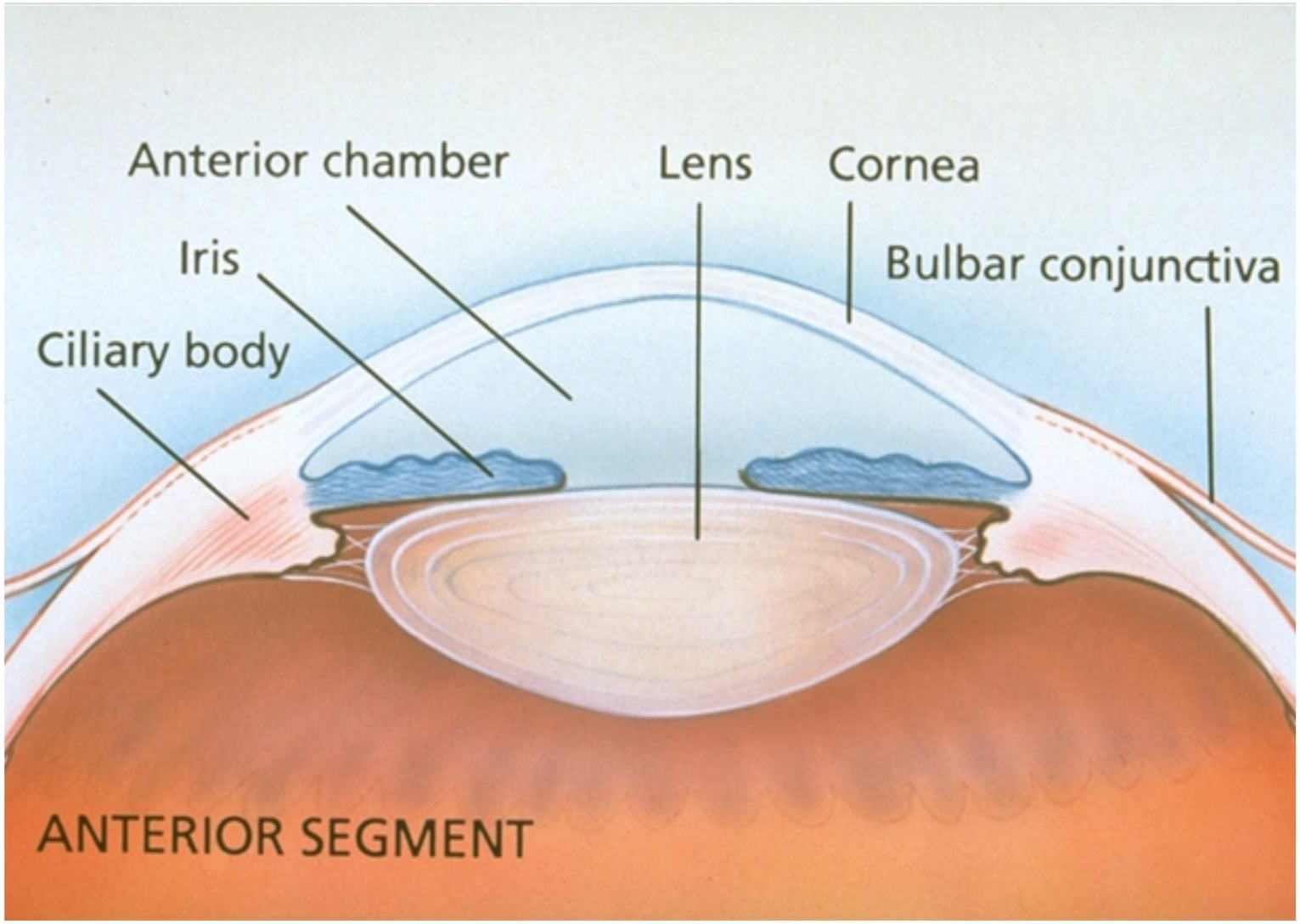
Anterior chamber
Lens
Cornea
Iris
Bulbar conjunctiva
Ciliary body
ANTERIOR SEGMENT

Corneal Abrasion

- Causes
  - Trauma
  - Welding Burn
  - Contact Lens Overwear
- Symptoms
  - Tearing
  - Pain
  - Photophobia
- Factors
  - Size
  - Location

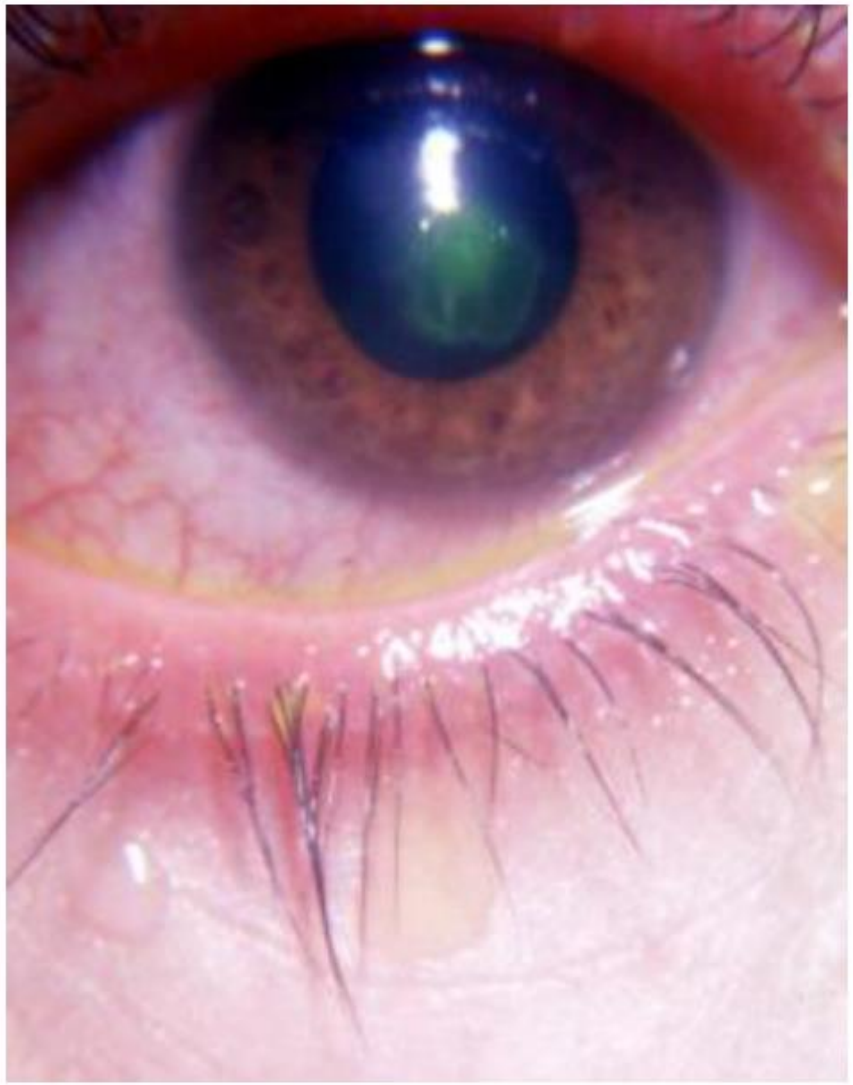

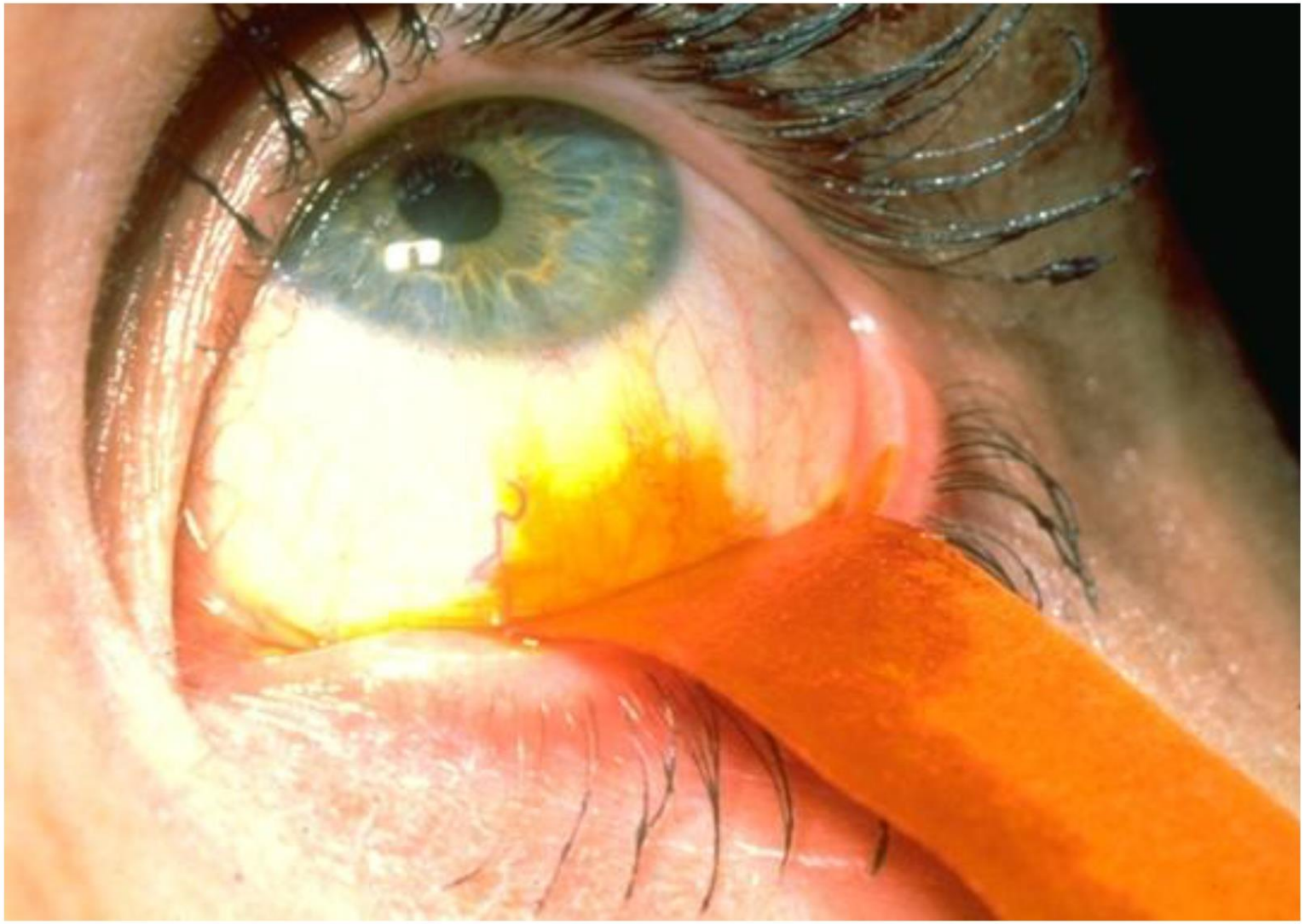

Fluorescein dye strip applied to the conjunctiva

Corneal abrasion (Cobalt Blue)

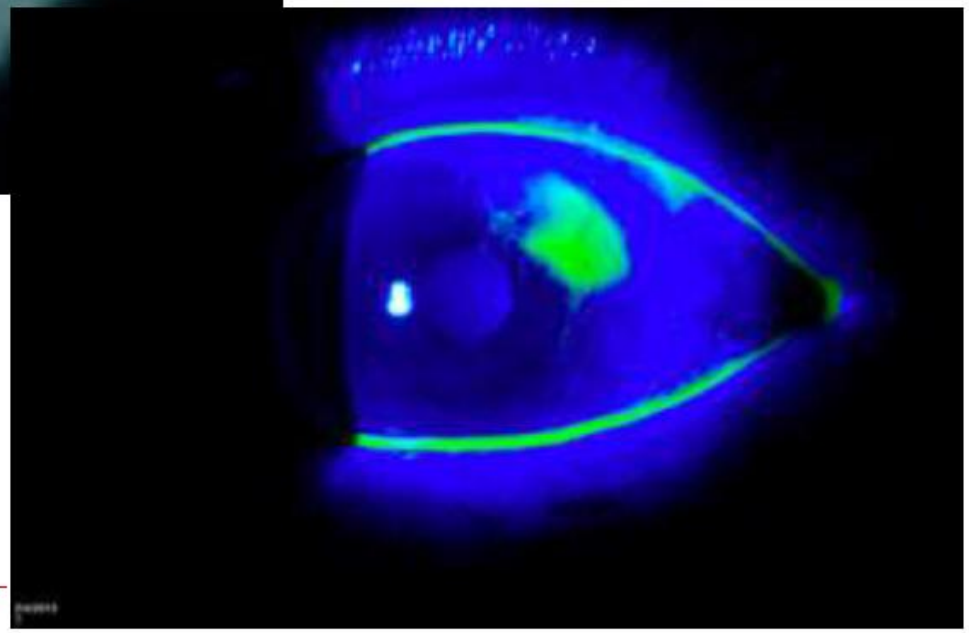

3rd most common cause of red eye!

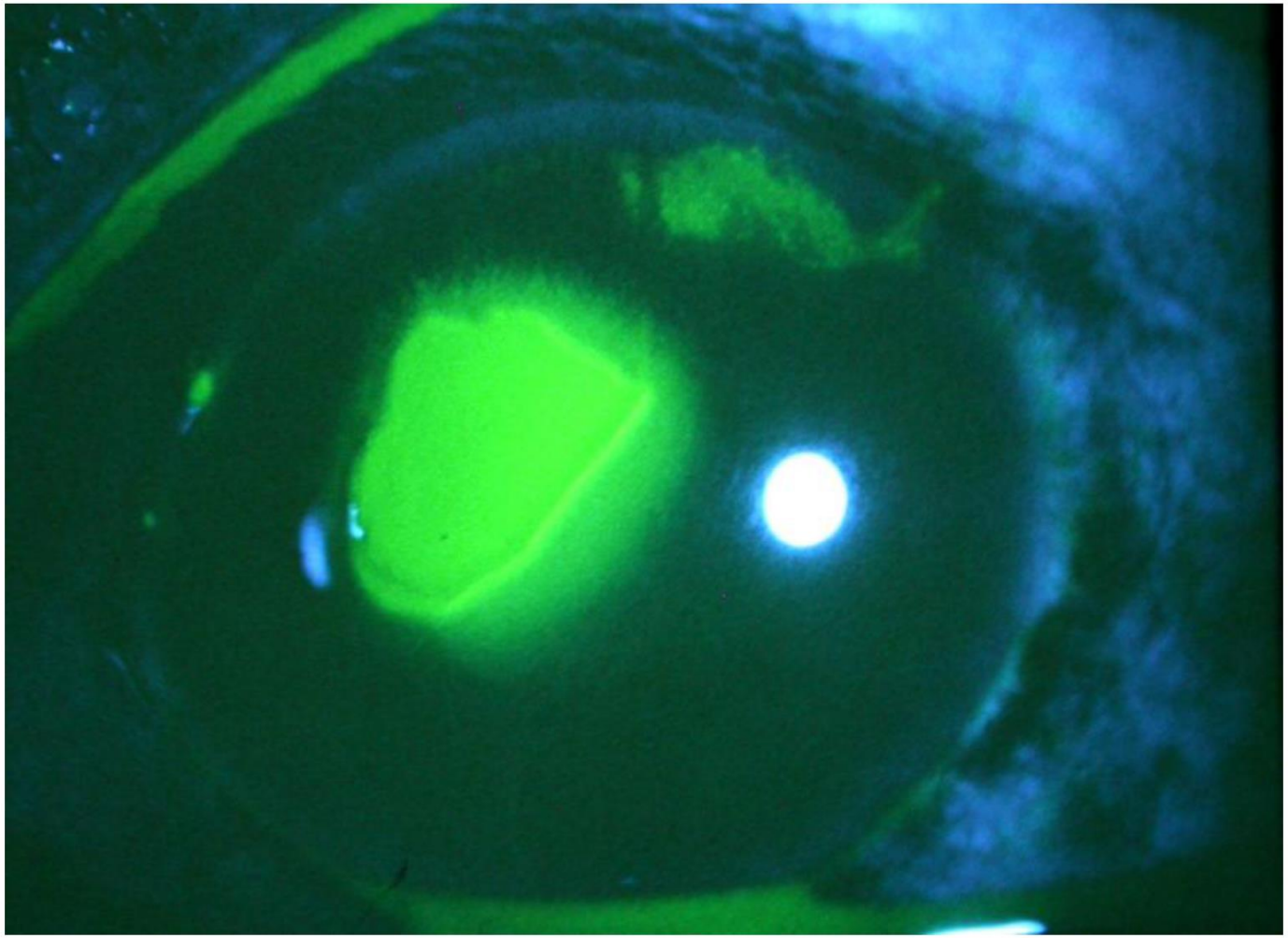

Corneal abrasion, stained with fluorescein and viewed with cobalt blue light

CORNEAL ABRASION: MANAGEMENT

- Goals:
  - Promote rapid healing
  - Relieve pain
  - Prevent infections
- Treatment:
  - 1% cyclopentolate
  - Topical antibiotics
    - Drops (eg, fluoroquinolone, others) or ointment (eg,
    - erythromycin, bacitracin/polymyxin)
  - ± Pressure patch x 24–48 hours
  - ± Oral analgesics

Corneal Abrasion Treatment

- **Antibiotic drops/ointment**
- Consider NSAID topical (Ketoralac)
- No evidence that patching is beneficial (may be harmful)
- Re-examine patient the following day
  - If central visual axis and/or ≥4mm in size
- Refer if corneal abrasion is not healing

Applying a pressure patch

Foreign Bodies

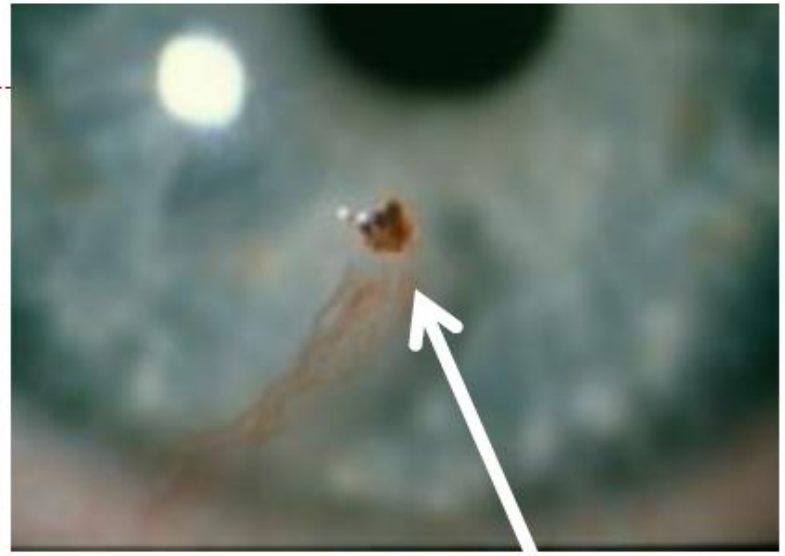

Corneal surface FB

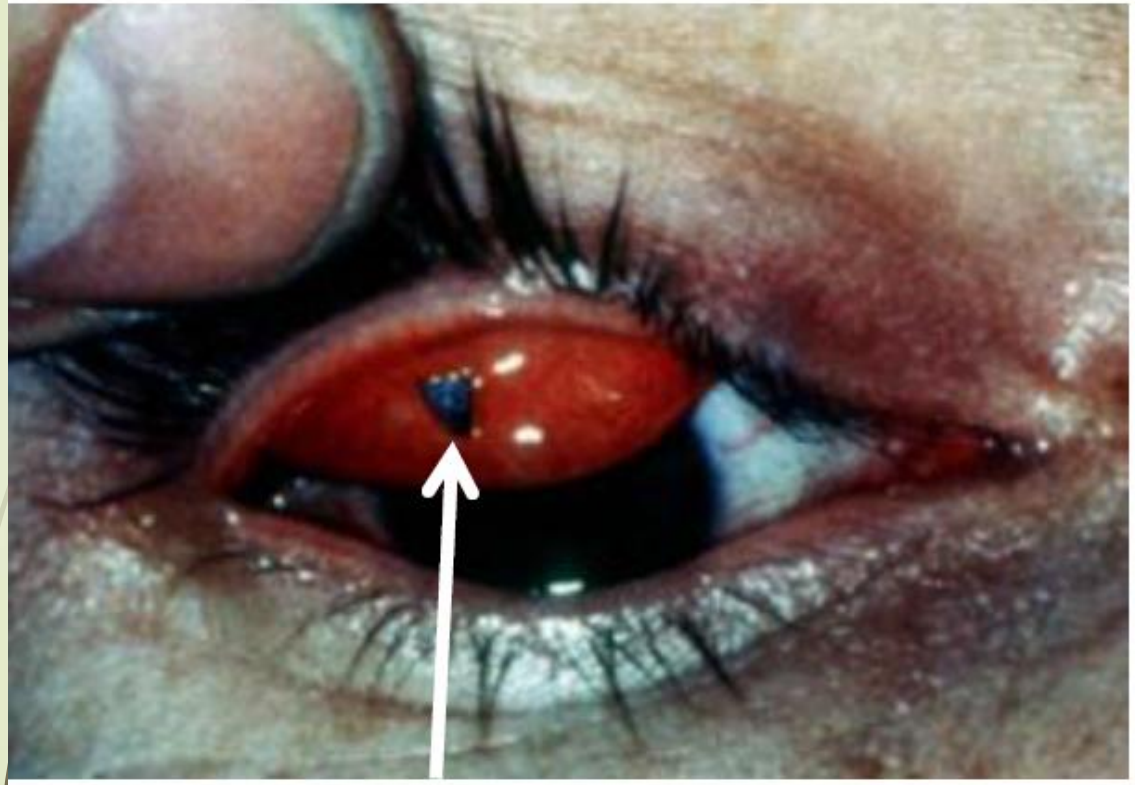

Upper eyelid FB

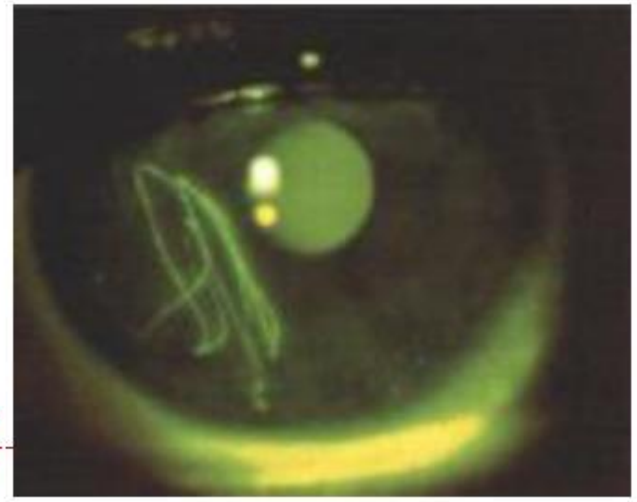

CHEMICAL INJURY

- A true ocular emergency
- Requires immediate irrigation with nearest source of water
- Management depends on offending agent

Chemical burn: alkali

Chemical Burn/Injury

- Alkali
- Acidic
- Refer to Ophthalmologist
- "Dilution is the solution to pollution."

http://www.emergency-shower.org/combination-shower-eyewash/

Hyphema

INFLAMMATORY CONDITIONS CAUSING A RED EYE:

- Episcleritis
- Scleritis
- Anterior uveitis (iritis)

Episcleritis

- Usually unilateral
- Episcleral vessel inflammation - autoimmune
- Rapid onset
- Redness confined to one sector
- Duration: 7 – 10 days
- No treatment necessary
  - NSAID drugs may be prescribed

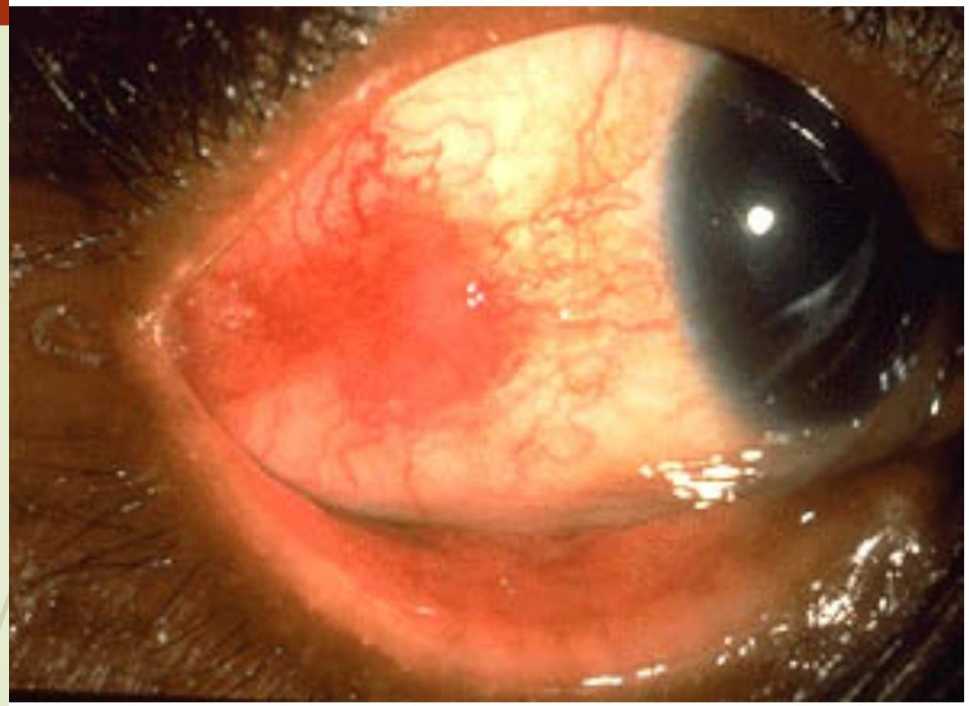

Episcleritis

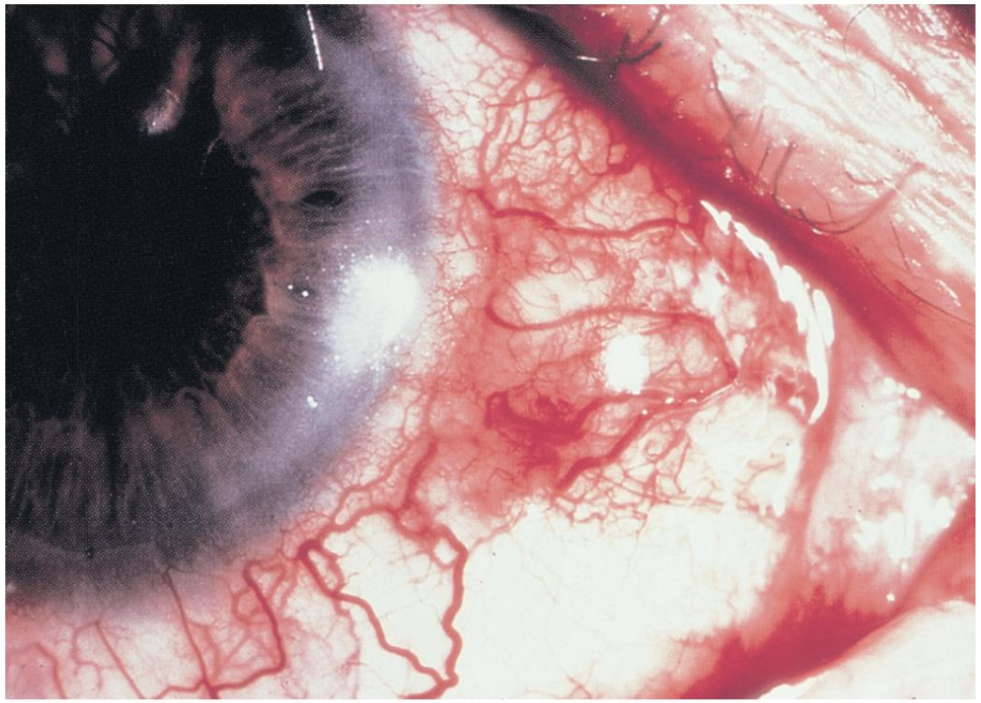

Scleritis

Scleritis

- Intense inflammation and **severe, deep eye pain**
- Associated with:
  - Rheumatoid arthritis
  - Inflammatory bowel disease
- Refer to Ophthalmologist

IRITIS

Signs and Symptoms

- Circumlimbal redness
- Pain
- Photophobia
- Decreased vision
- Miotic pupil

Rule Out

- Systemic inflammation
- Trauma
- Autoimmune disease
- Systemic infection

Recognize and refer.

UVEITIS: SLIT LAMP FINDINGS

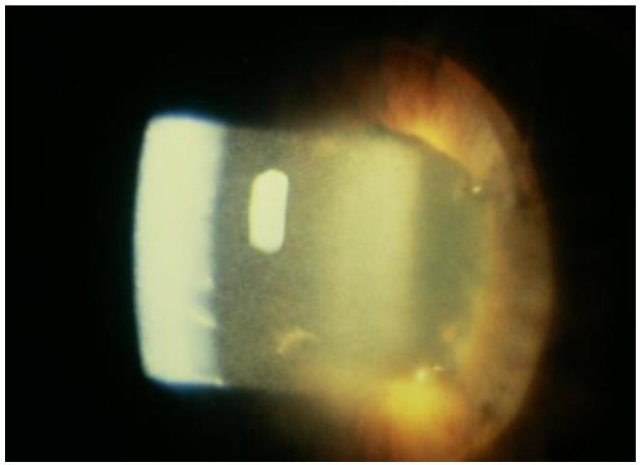

White cells in anterior chamber

Hypopyon

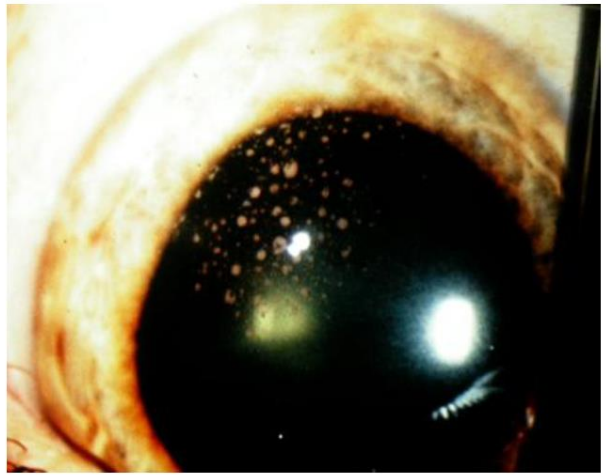

Keratic precipitates

(Anterior) Uveitis

- Iris and ciliary muscle inflammation
- Caused by autoimmune disease or trauma
  - Also can be idiopathic
- Signs:
  - Ocular pain
  - Limbal/Ciliary flush
  - Irregularity of pupil (shape)

- Refer to Ophthalmologist/Optometrist

Anterior uveitis (Iritis)

- Inflammation of the anterior uveal tract
- Idiopathic (70%)
- Associated with systemic disease:
  - Sarcoid
  - Ankylosing spondylitis
  - Inflammatory bowel disease
  - Reiter's syndrome
  - Psoriatic arthritis
  - Juvenile Chronic arthritis
- Infection
  - Bacteria- TB, syphyllis, leprosy
  - Viral: HSV, HZV, HIV
  - Fungal
  - Infestation
- Ocular entities:
  - Post-trauma
  - Lens-induced
  - Post-op
  - Retinoblastoma, lymphoma

Anterior uveitis (Iritis)

- Symptoms/Signs
  - Pain (ache)
  - Photophobia
  - Perilimbal conjunctival injection
  - Blurred vision
  - Pupil miotic / poorly reactive
- Slit-lamp examination:
  - flare (protein) in AC
  - cells in AC
  - Keratic precipitates (WBC) on the back of the cornea
  - Hypopyon

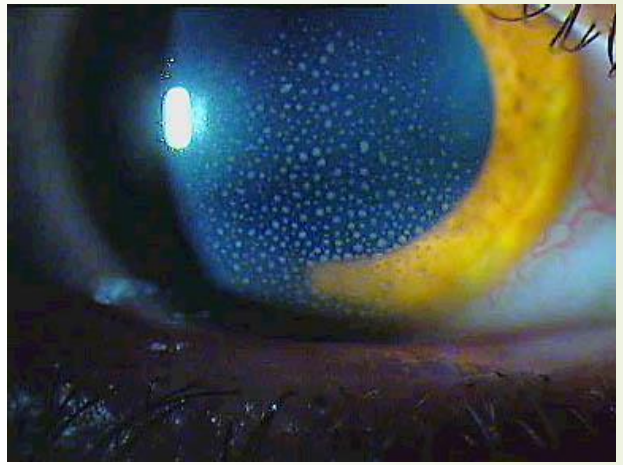

Anterior uveitis (Iritis)

- Repeated attacks
- Investigations CXR, lumbar XR, autoimmune serology, HLA B27 Bilateral cases or severe cases
- Treatment
  - Mydriatic / cycloplegics to break synechiae, comfort
  - Topical steroids, depending on severity, initally can be ½ hourly
  - May need sub conjunctival steroid if very severe

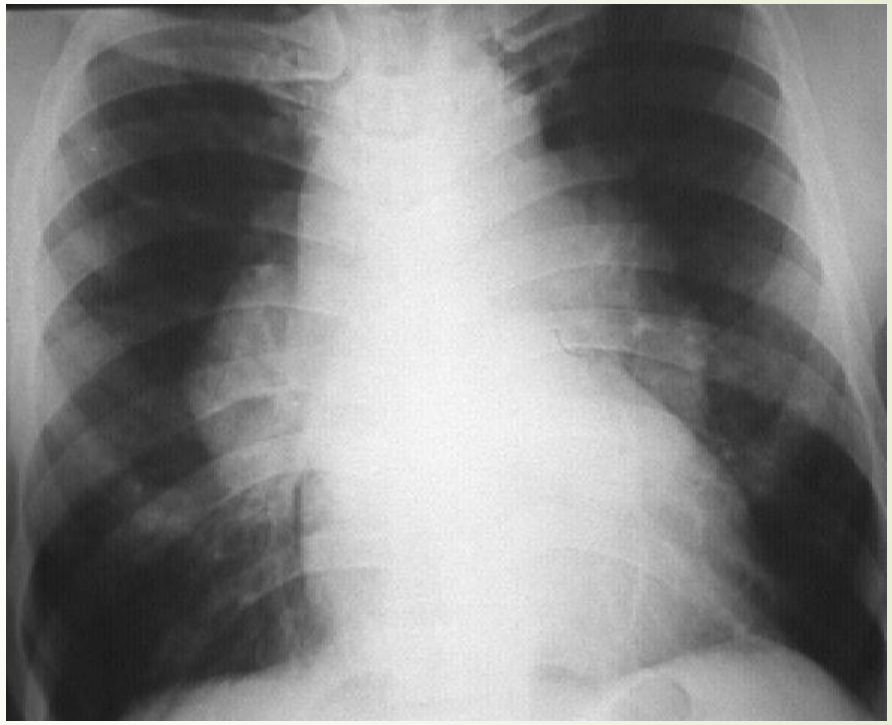

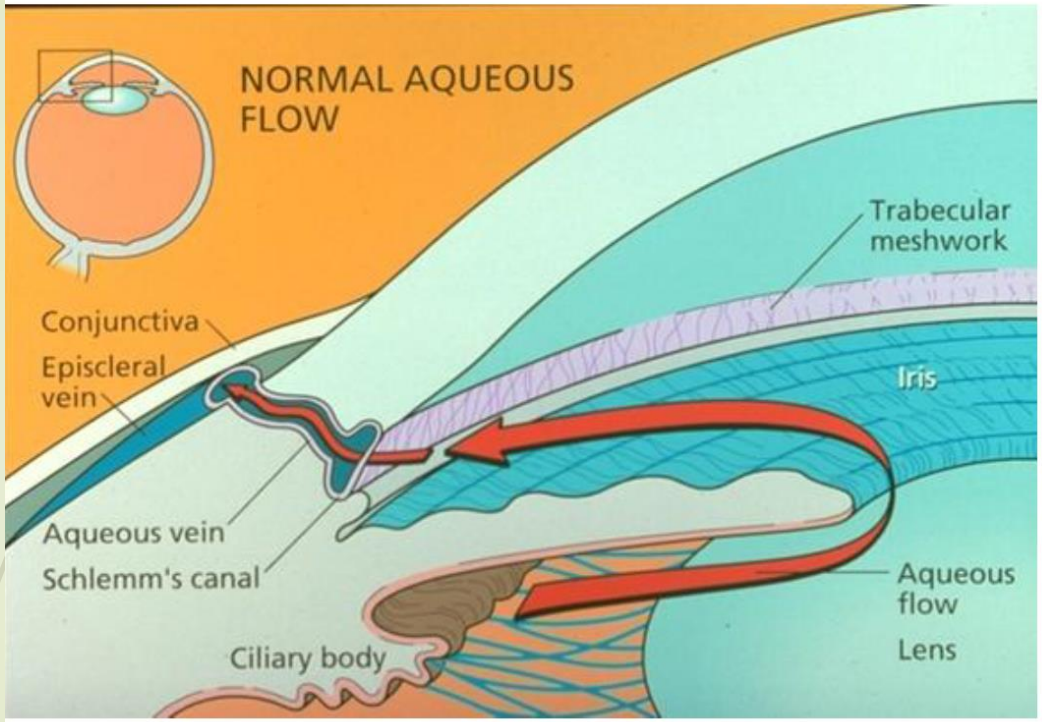
NORMAL AQUEOUS FLOW
Trabecular meshwork
Conjunctiva
Episcleral vein
Iris
Aqueous vein
Schlemm's canal
Aqueous flow
Ciliary body
Lens

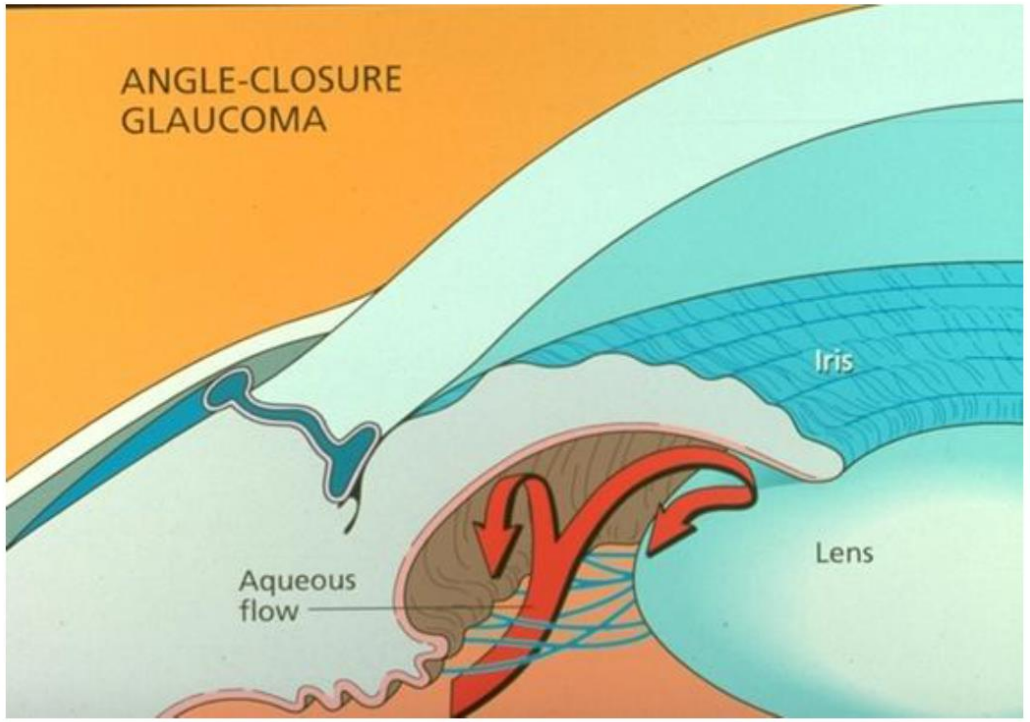
ANGLE-CLOSURE GLAUCOMA
Iris
Lens
Aqueous flow

ACUTE GLAUCOMA: SIGNS AND SYMPTOMS

- Red eye
- Severe pain in, around eye
- Frontal headache
- Blurred vision, halos seen around lights
- Nausea, vomiting
- Pupil fixed, mid-dilated, slightly larger than contralateral side
- Elevated IOP
- Corneal haze

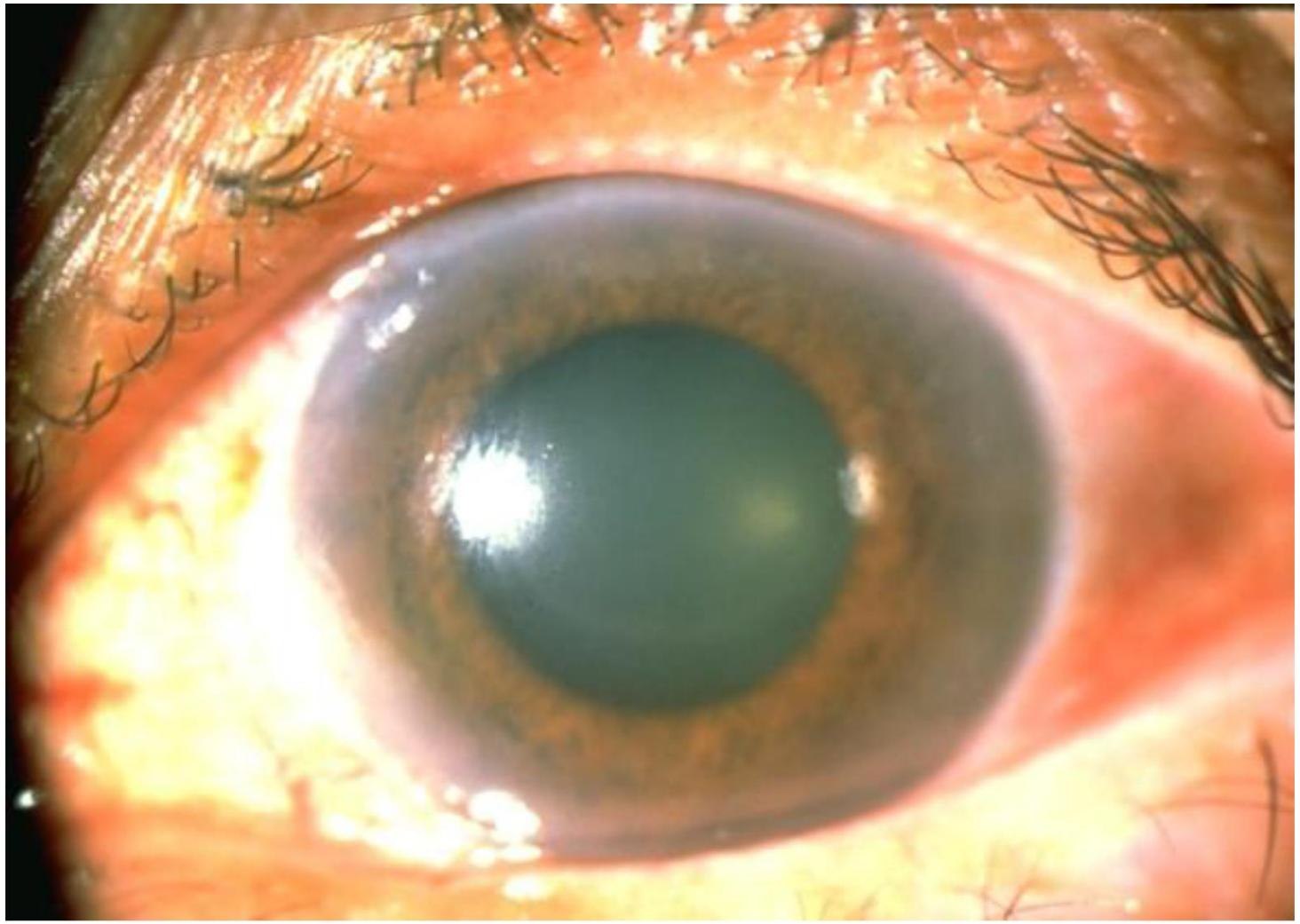

Acute angle-closure glaucoma

ACUTE GLAUCOMA: INITIAL TREATMENT

- Pilocarpine 2% drops q 15 min x 2
- Timolol maleate 0.5%, 1 drop
- Apraclonidine 0.5%, 1 drop
- Acetazolamide 500 mg po or IV
- IV mannitol 20% 300–500 cc

Thanks